

Second opinion pathology report for radical prostatectomy specimen

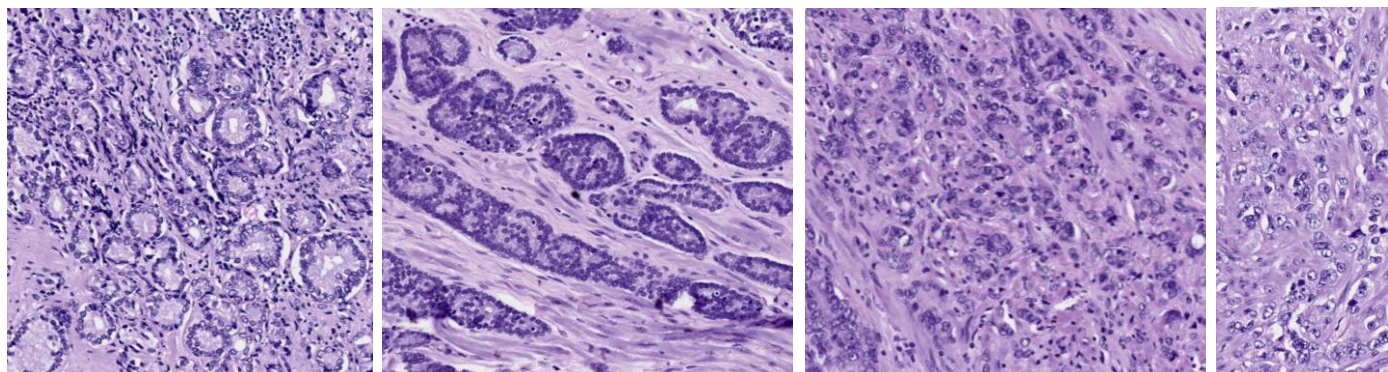
Patient first name, last name: [REDACTED]	Date of birth: [REDACTED] years old, Male
Patient identifiers: [REDACTED]	
TwiceView examination number: [REDACTED]	Date of request: [REDACTED]

DISCLAIMER: This second opinion report is intended to support clinical decisions concerning patient management and should be considered as a part of diagnostic workup prior to treatment. If the second opinion is discordant in some aspects with primary histopathology report, as it may happen concerning subjective nature of many histopathological assessments, discordances should ideally be discussed with pathologists issuing primary report to provide clear information for treating physician before any treatment decisions are made. This second opinion is not intended for legal purposes and must not be used after the introduction of treatment at a given stage.

Summary diagnosis

Acinar adenocarcinoma of the prostate, Gleason 4+5, Grade Group 5

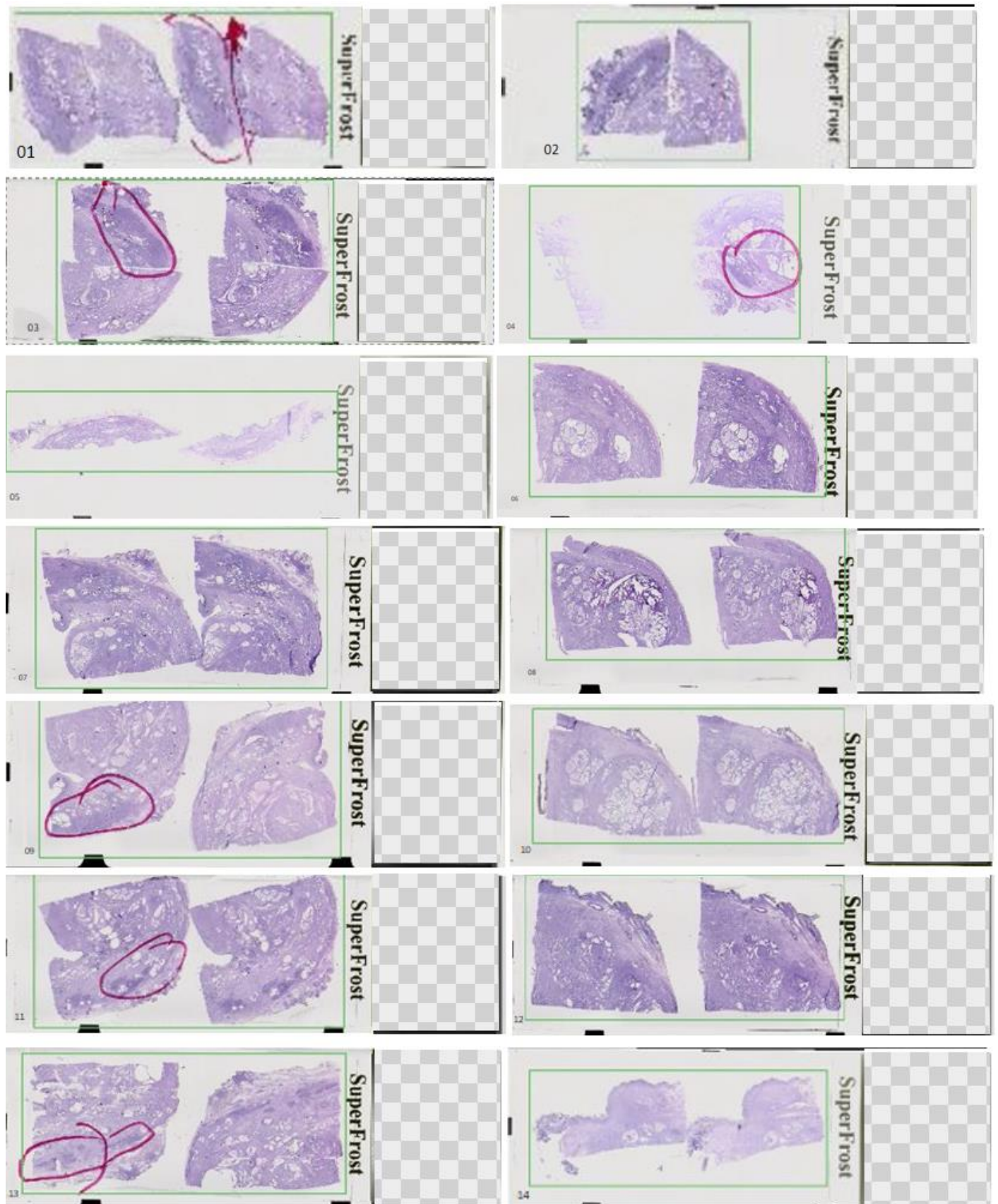
Gleason 4 – 95.4%, Gleason 5 – 3.4%, Gleason 3 – 1.2%. Cribriform glands present.

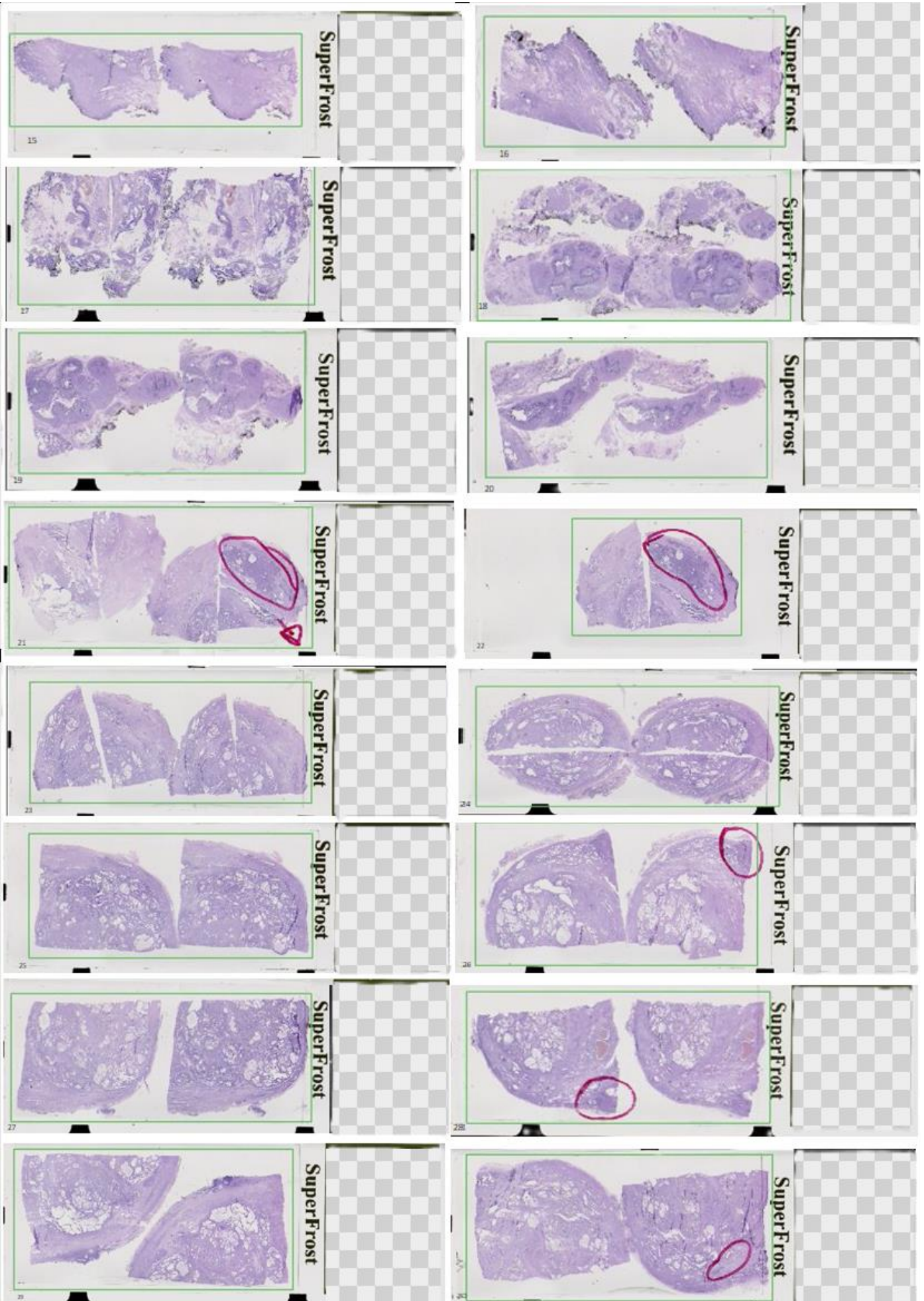


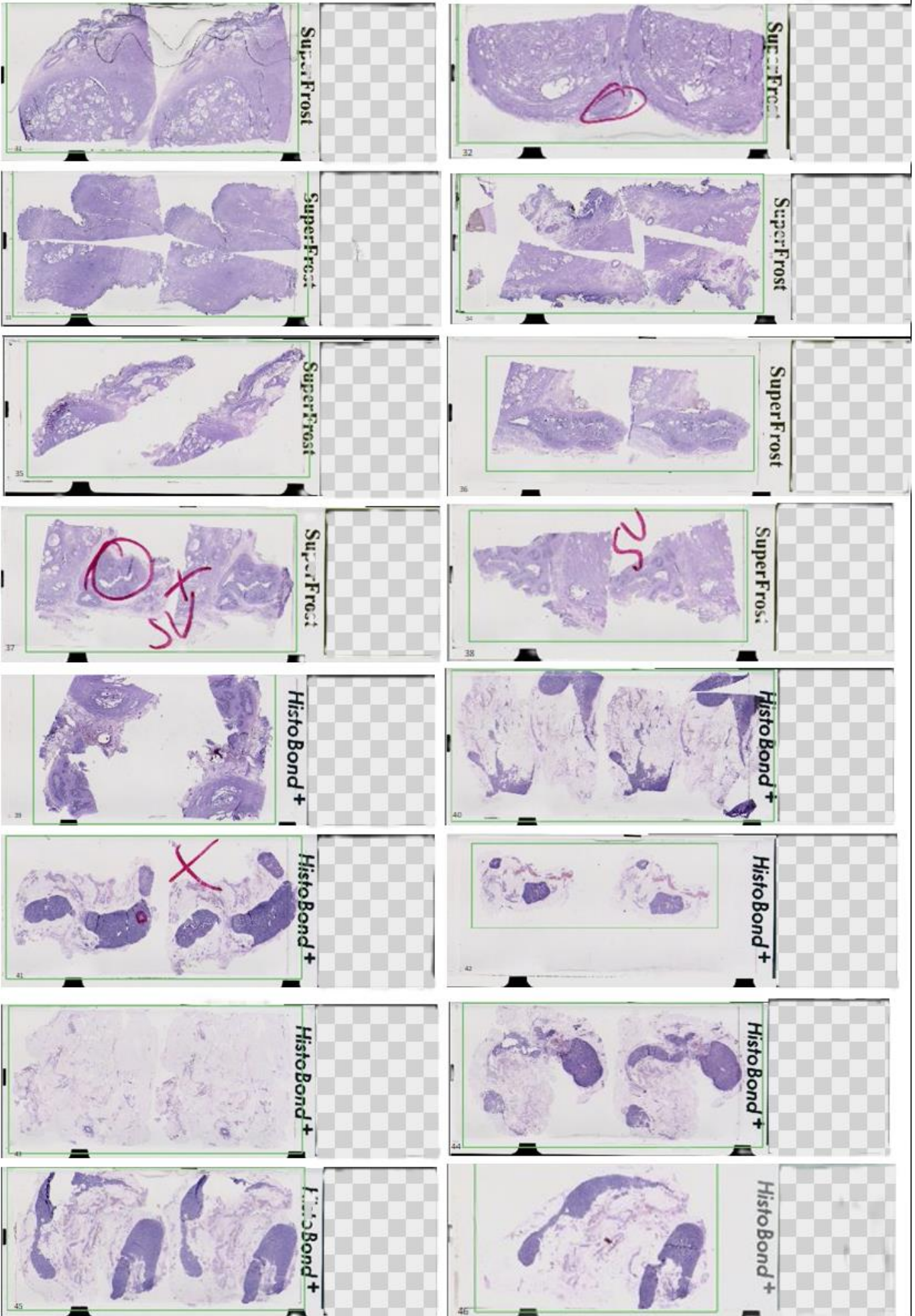
Intraglandular extent	Tumor present in the apex and posterior part of the prostate on both sides . Tumor involves about 20% of the prostate volume.
Extraprostatic extension	Present , extent non-focal (multifocal, bilateral)
Seminal vesicle invasion	Present, bilateral
Urinary bladder neck invasion	Not identified
Intraductal carcinoma of prostate	Not identified
HGPIN	Present
Margin status	Not involved , closest distance to inked margin – 0.15 mm
Lymphovascular invasion	Present
Lymph node status	Regional (pelvic) lymph nodes examined: 10 Number of lymph nodes involved: 2 Laterality: Bilateral metastatic involvement Maximum dimension of the largest metastatic deposit: 7.17 mm Extranodal extension (ENE): Present
pT3bN1 (AJCC TNM 8 th edition)	

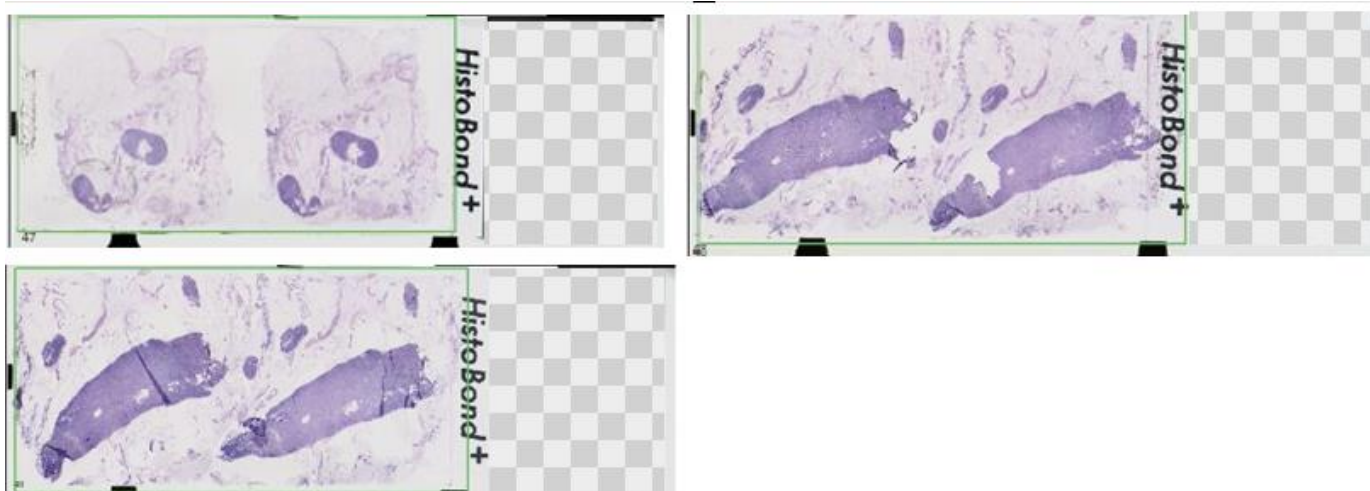
Detailed pathology report

Slides submitted for second opinion assessment









BLOCK/SLIDE IDENTIFICATION KEY

Left lobe	
Apex	██████████
Lobe	████████████████████████████████████████
Base	██████████
Seminal vesicle	██████████
Right lobe	
Apex	██████████
Lobe	████████████████████████████████████████
Base	██████████
Seminal vesicle	██████████
a=anterior, p=posterior	

CLINICAL INFORMATION

Malignant neoplasm of the prostate. Other clinical information not provided.

SPECIMEN WEIGHT (weight of the prostate gland without the seminal vesicles)

Not provided in the primary histopathological report.

SEMINAL VESICLES

Present

LYMPH NODES

Present, bilateral

HISTOLOGICAL TUMOR TYPE

Adenocarcinoma of the prostate (acinar, usual type)

HISTOLOGICAL GRADE

Gleason score – composite (global) method 4+5

ISUP Grade Group 5

Primary pattern - Gleason 4 – 95.4%

Secondary pattern – Gleason 5 – 3.4%

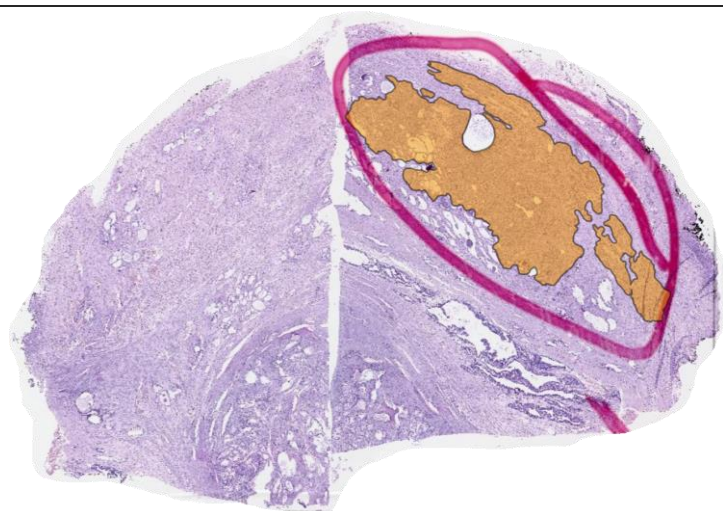
Tertiary pattern – Gleason 3 – 1.2%

Term	Area (microns ²)	Area (mm)	Share %
Gleason 3	5 297 684.99	47.47	1.2%
Gleason 4	435 529 948.62	798.05	95.4%
Gleason 5	15 505 273.06	119.89	3.4%
Sum	456 332 906.68	965.41	100.0%

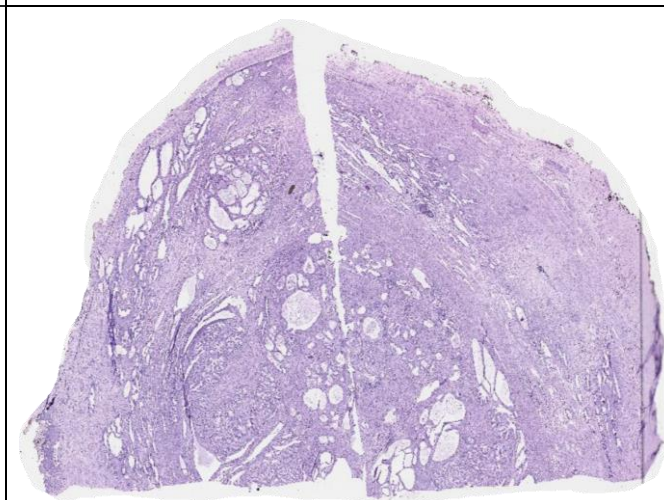
Apex of the prostate – right side

■ Gleason 3
 ■ Gleason 4
 ■ Gleason 5

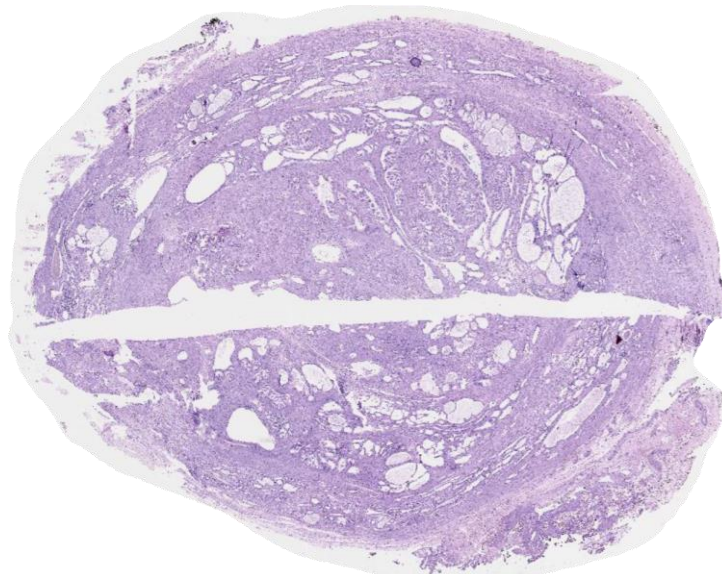
Slide 21



Slide 23



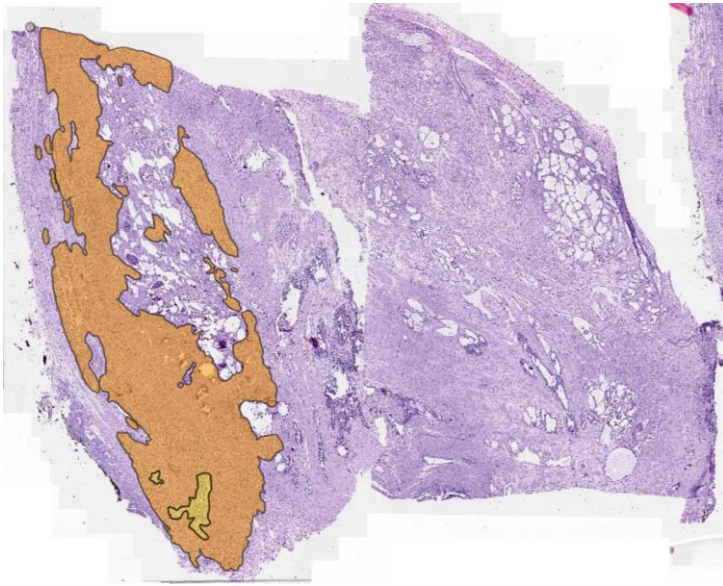
Slide 24



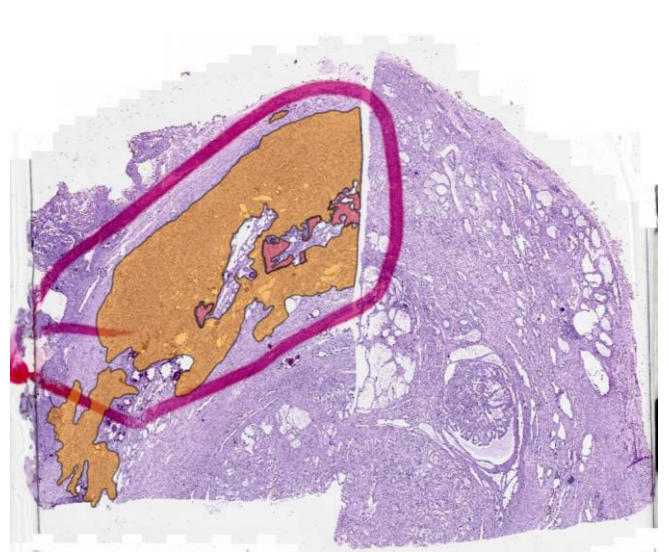
Apex of the prostate – left side

■ Gleason 3 ■ Gleason 4 ■ Gleason 5

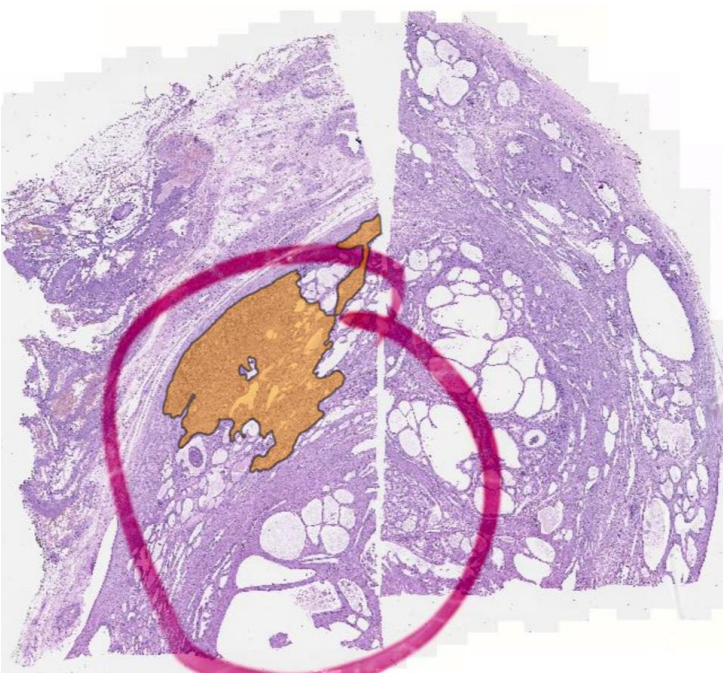
Slide 01



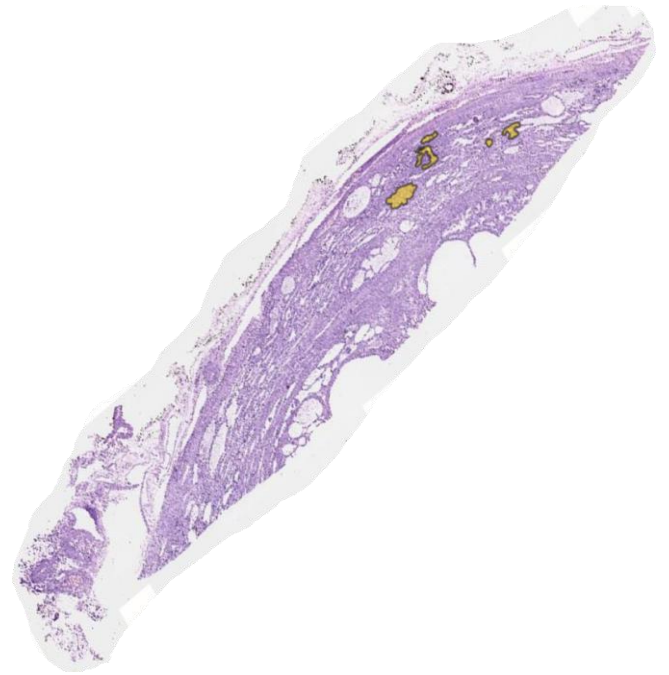
Slide 03



Slide 04



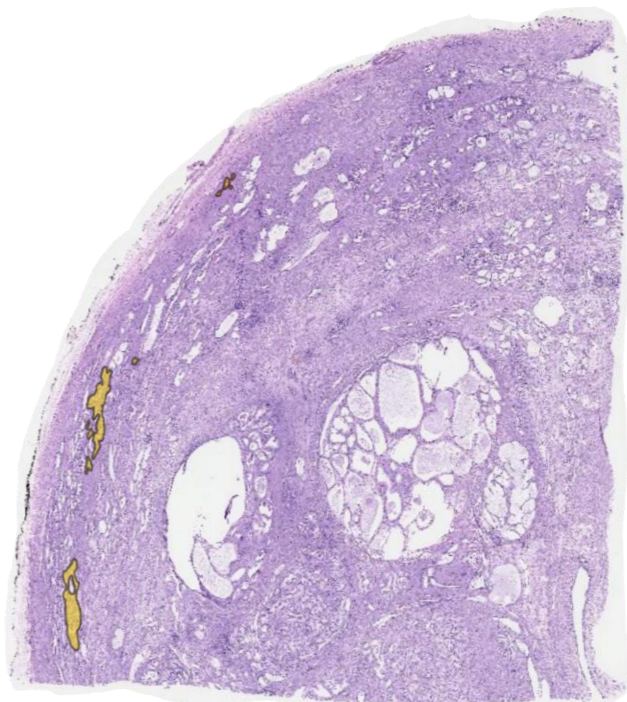
Slide 05



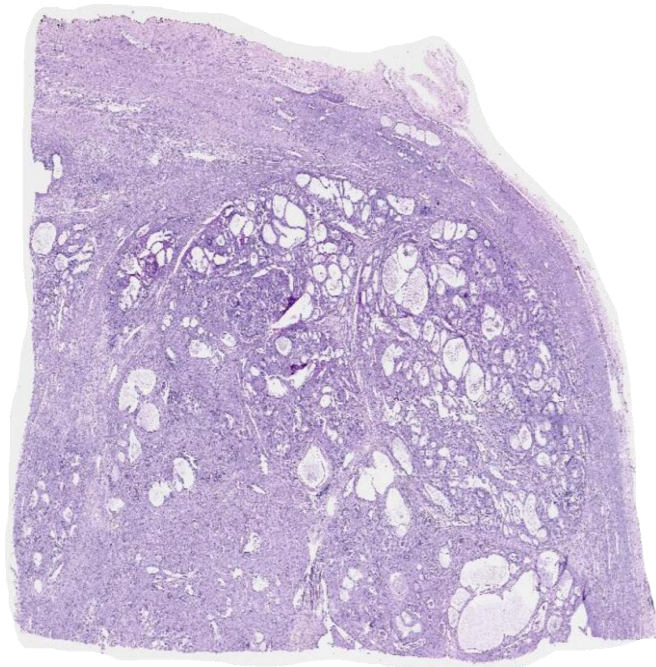
Right and left side of the prostate

■ Gleason 3
 ■ Gleason 4
 ■ Gleason 5

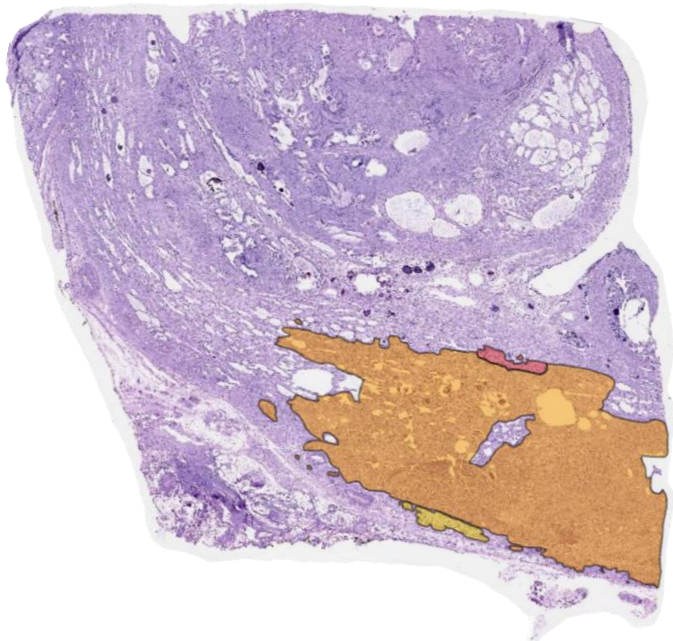
Slide 06 [redacted] Left anterior



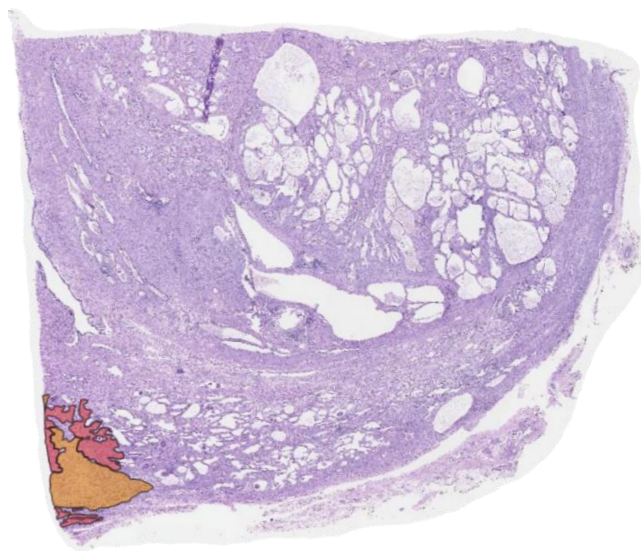
Slide 25 [redacted] Right anterior



Slide 07 [redacted] Left posterior

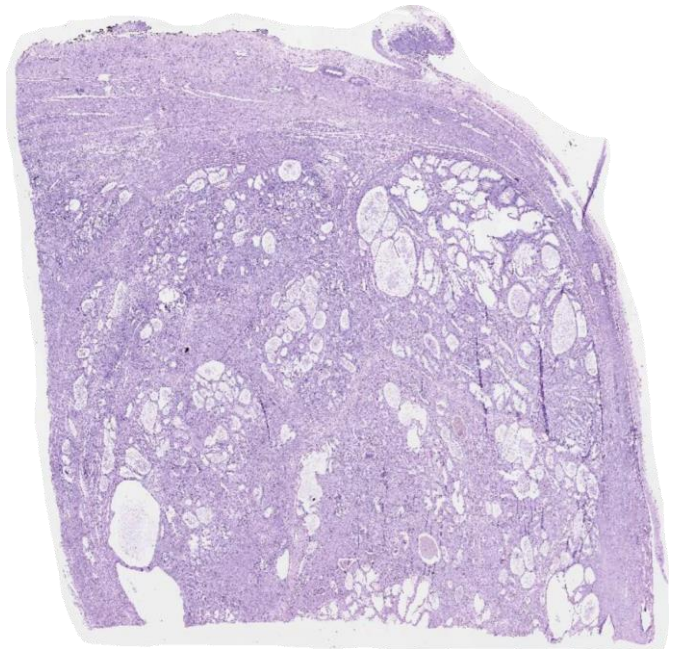
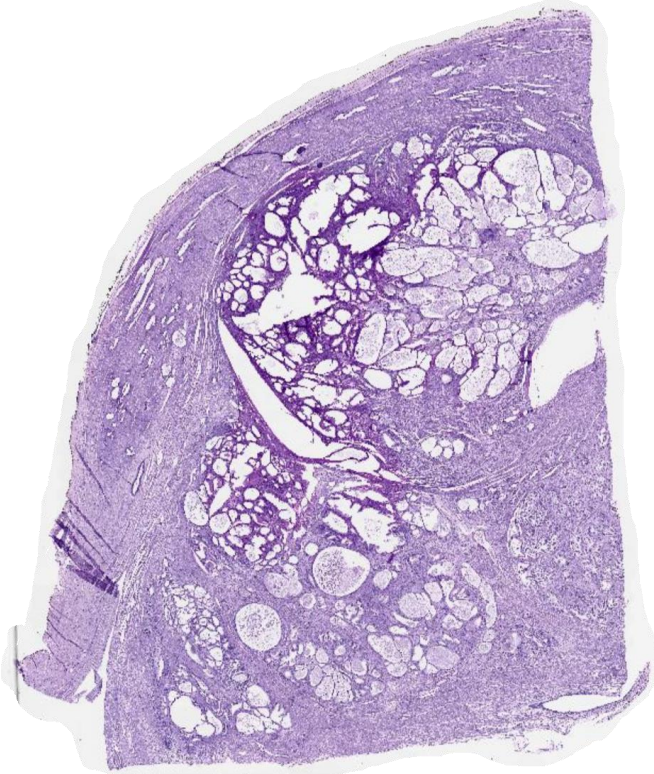


Slide 26 [redacted] Right posterior



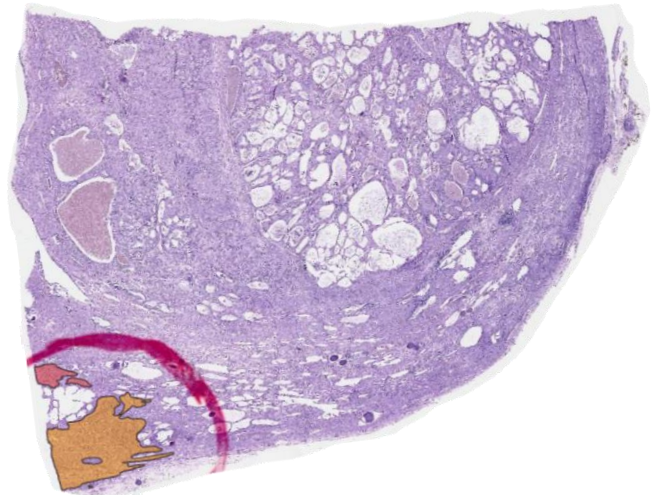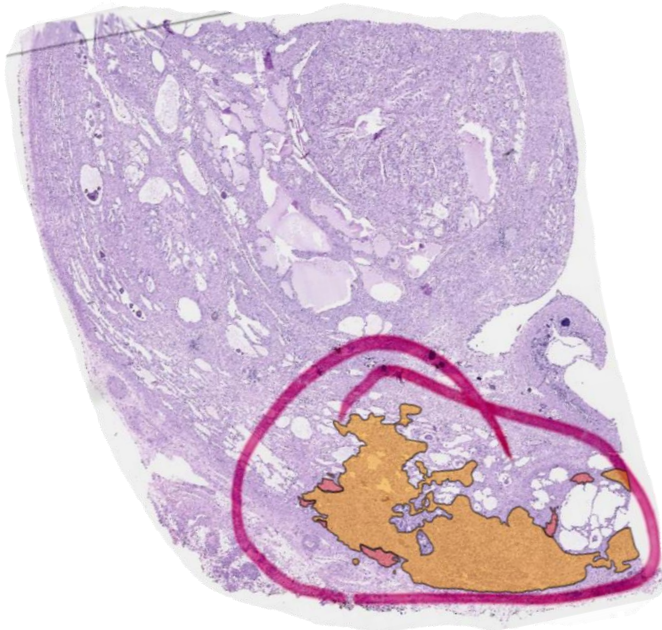
Slide 08 [redacted] Left anterior

Slide 27 [redacted] Right anterior



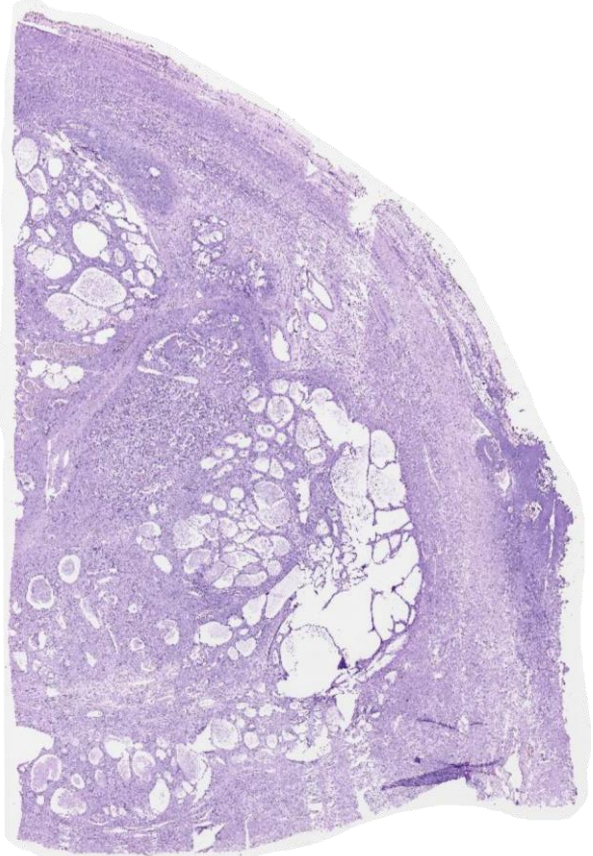
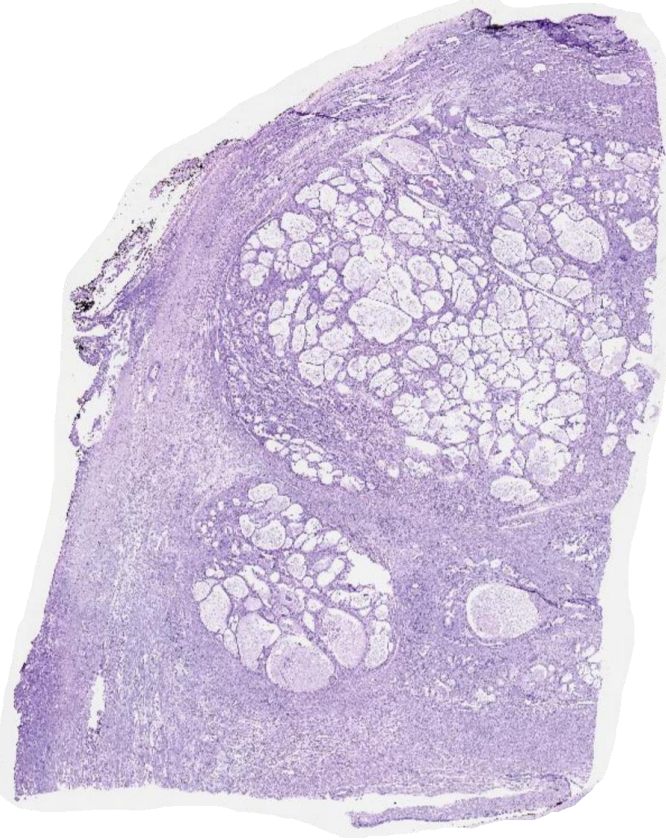Slide 09 [redacted] Left posterior

Slide 28 [redacted] Right posterior



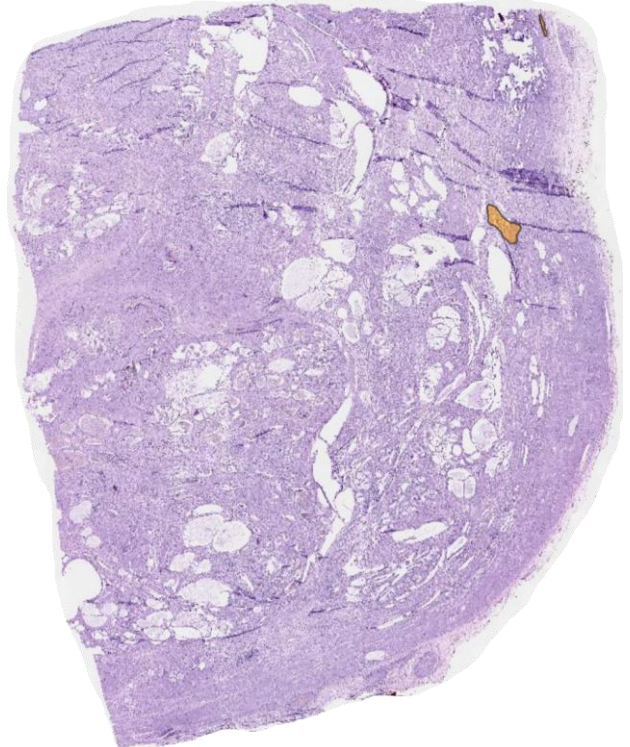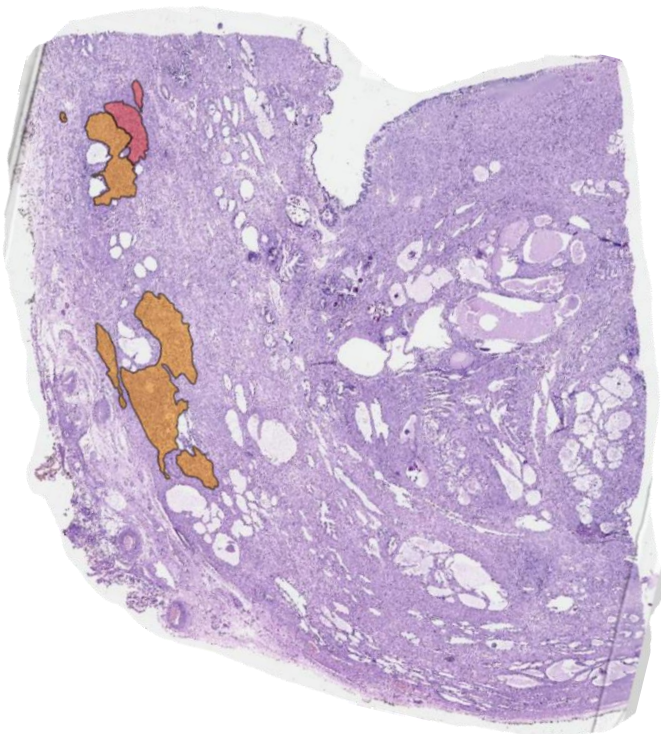
Slide 10 [redacted] Left anterior

Slide 29 [redacted] Right anterior



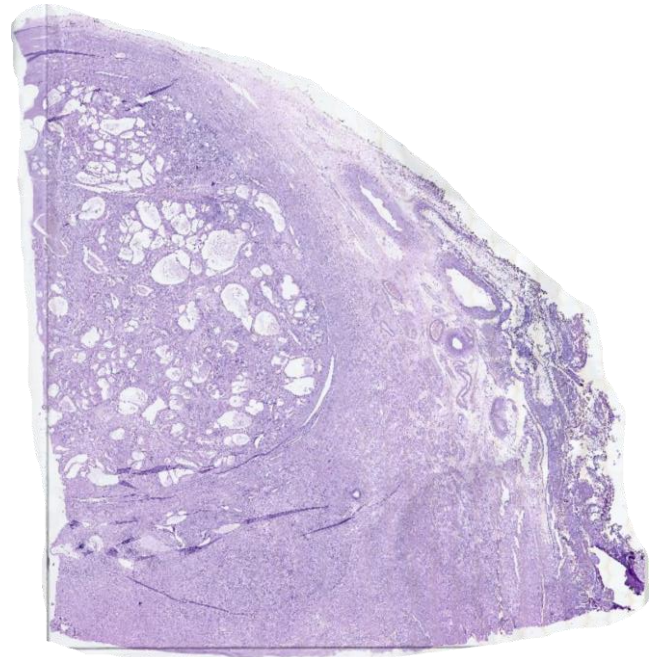
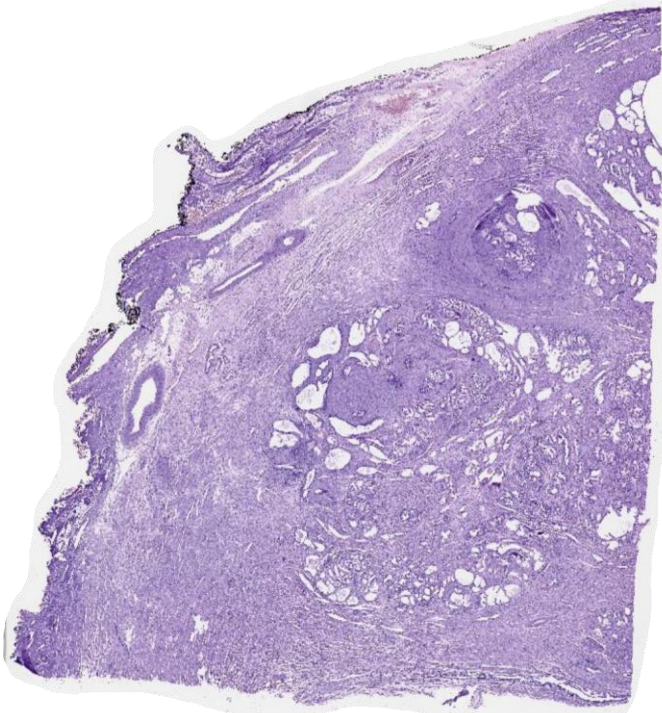
Slide 11 [redacted] Left posterior

Slide 30 [redacted] Right posterior



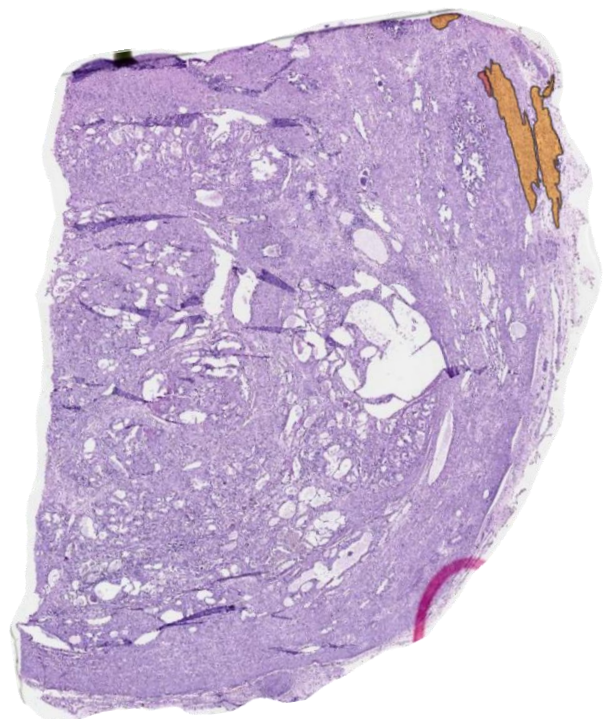
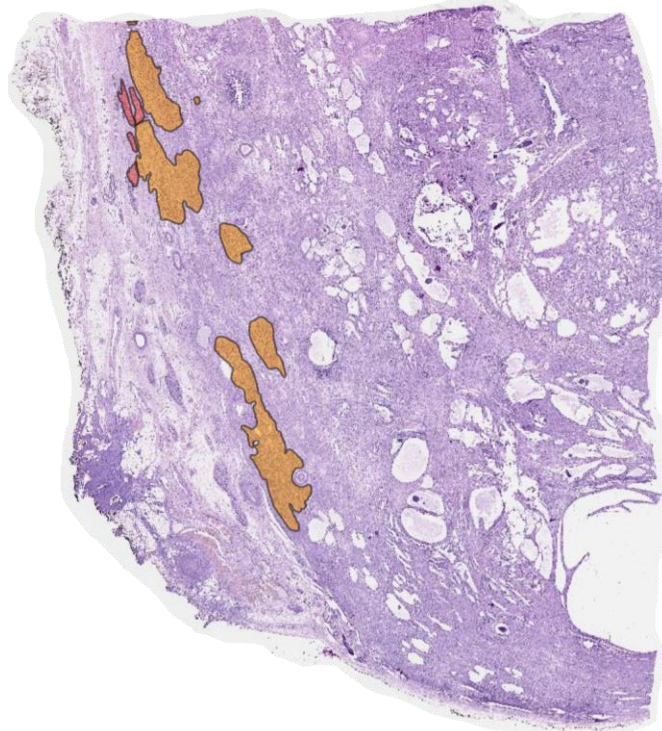
Slide 12 [redacted] Left anterior

Slide 31 [redacted] Right anterior



Slide 13 [redacted] Left posterior

Slide 32 [redacted] Right posterior

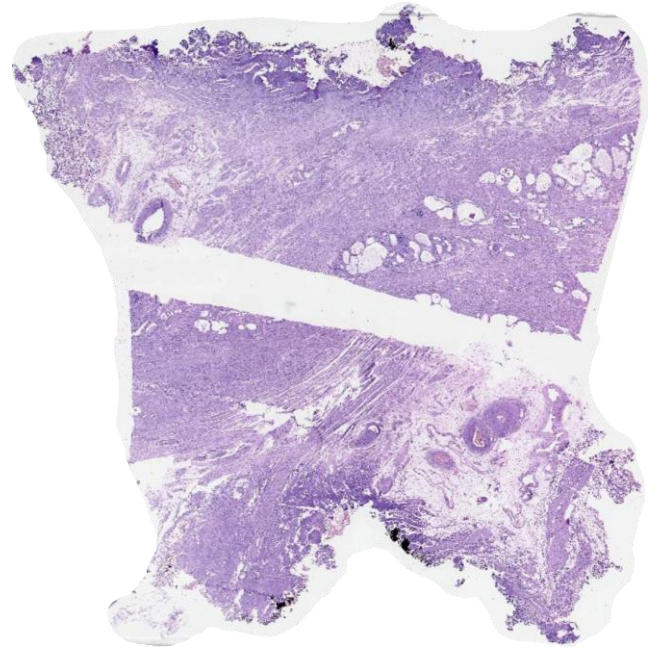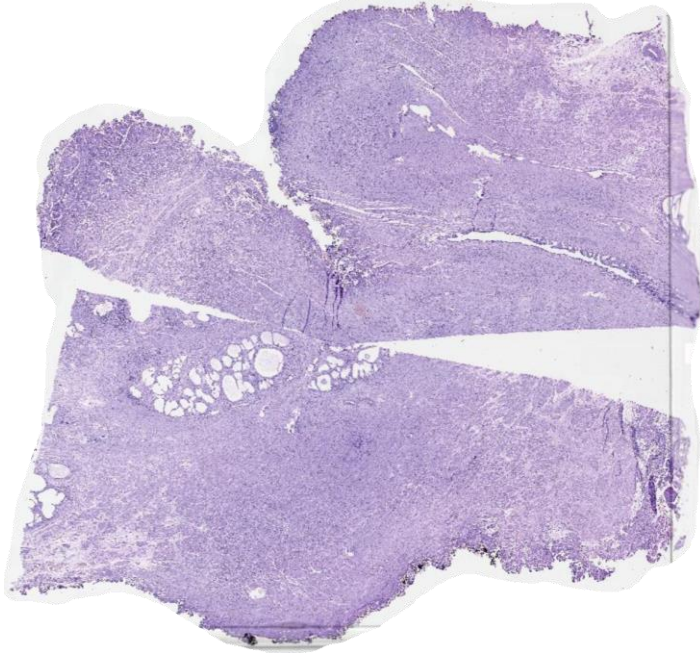


Base of the prostate – right side

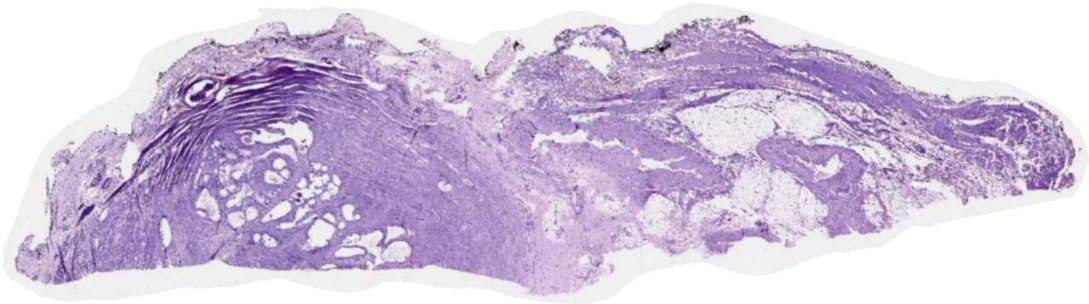
■ Gleason 3 ■ Gleason 4 ■ Gleason 5

Slide 33 [REDACTED]

Slide 34 [REDACTED]



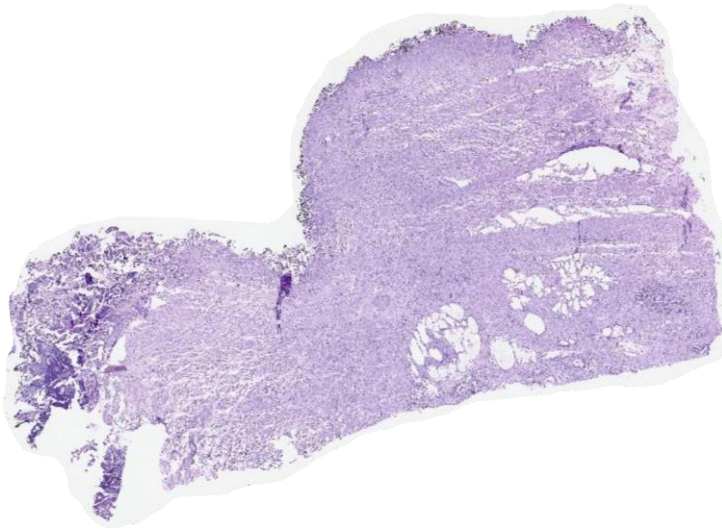
Slide 35 [REDACTED]



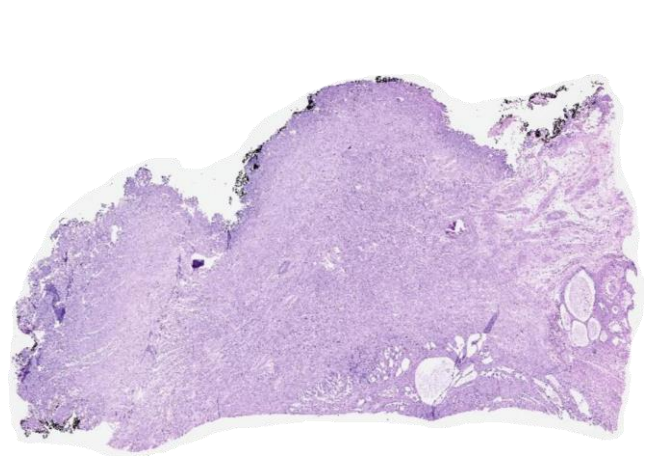
Base of the prostate – left side

■ Gleason 3 ■ Gleason 4 ■ Gleason 5

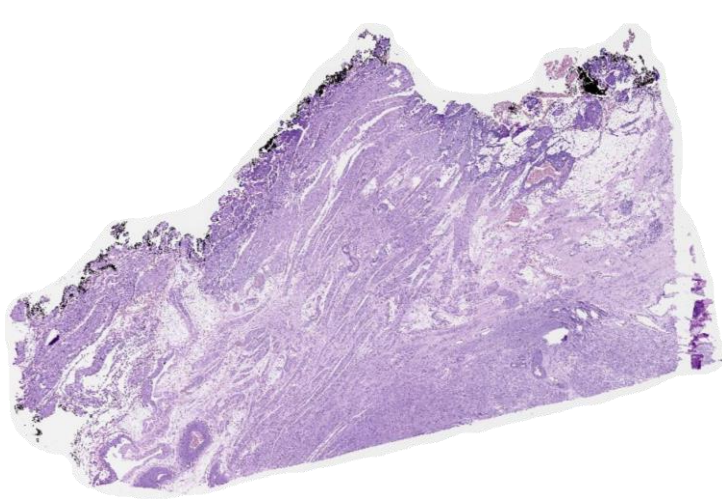
Slide 14 [REDACTED]



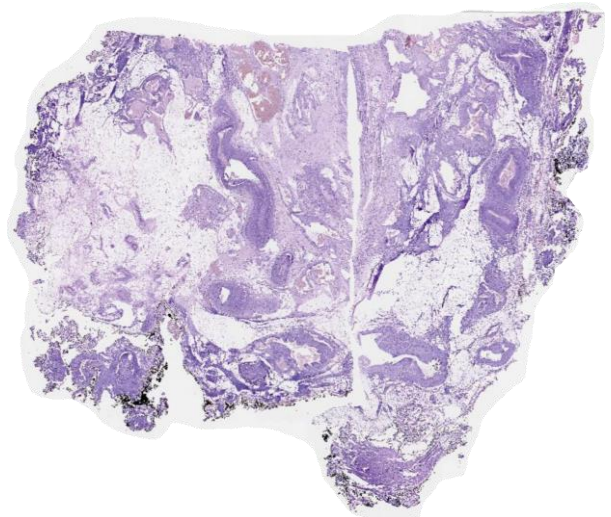Slide 15 [REDACTED]



Slide 16 [REDACTED]



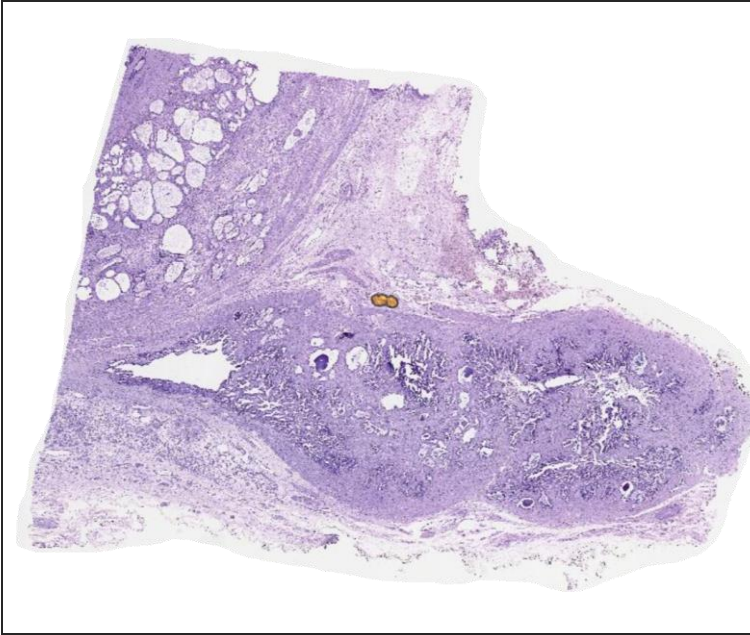
Slide 17 [REDACTED]



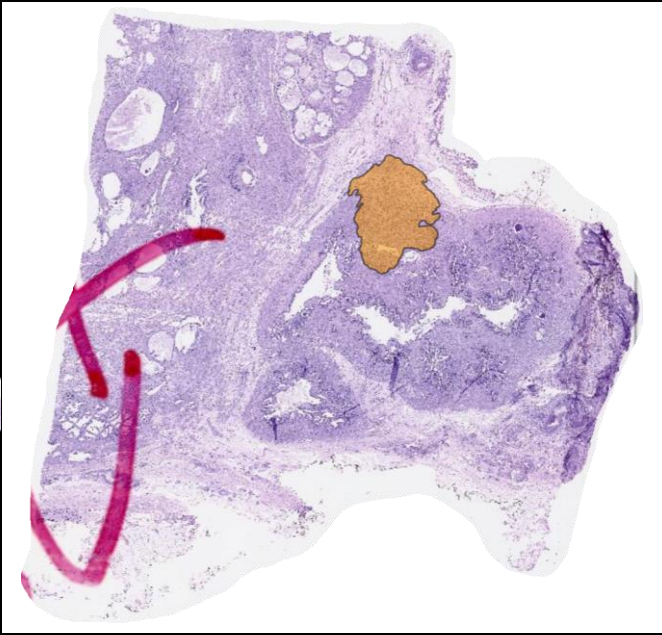Seminal vesicle – right side

■ Gleason 3 ■ Gleason 4 ■ Gleason 5

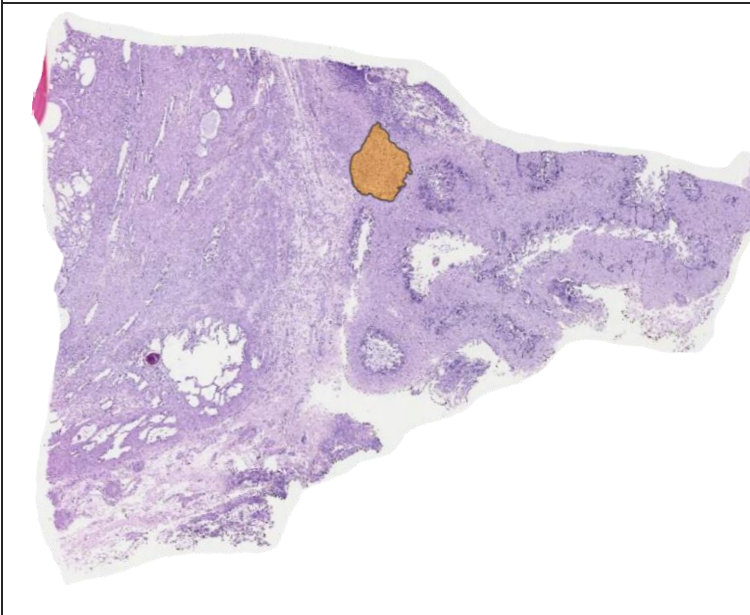
Slide 36



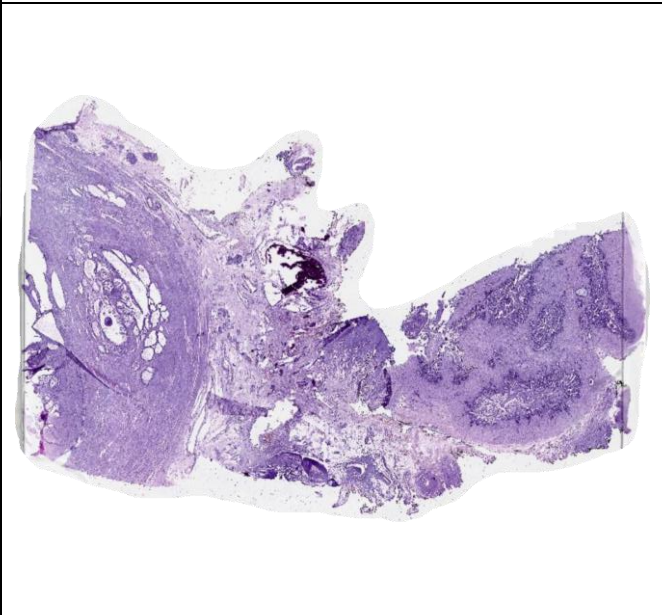Slide 37



Slide 38



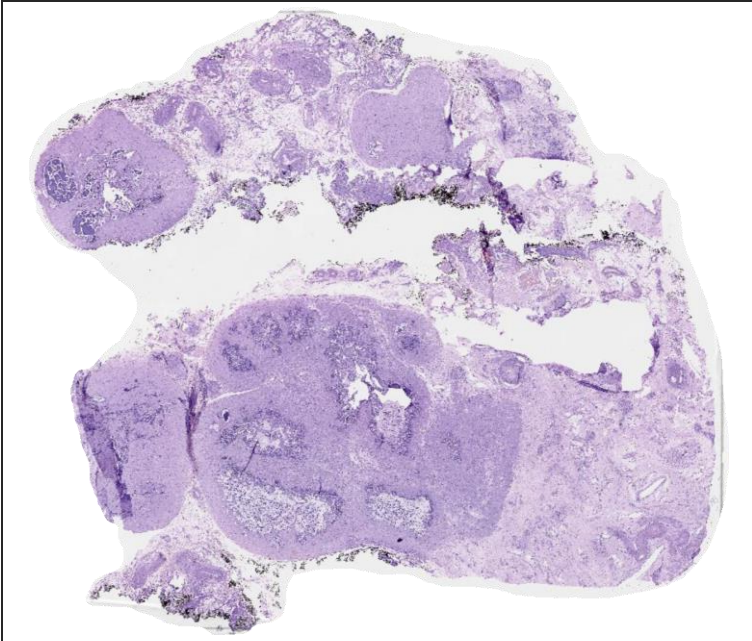
Slide 39



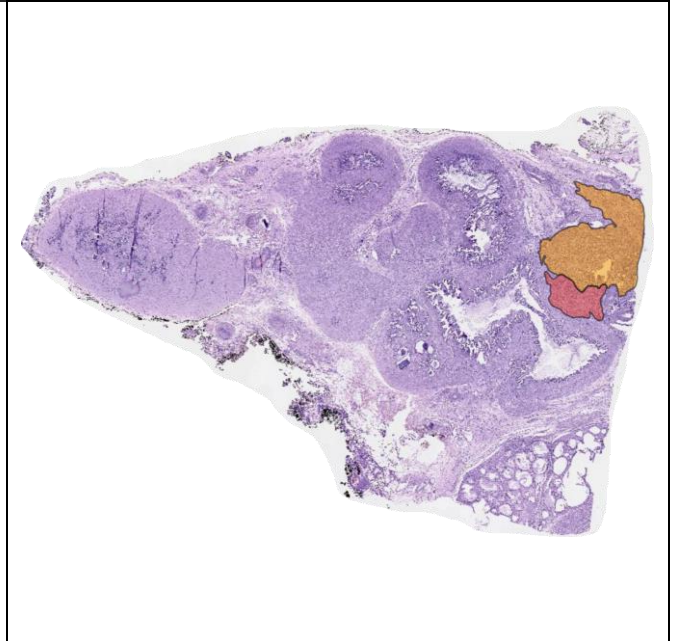
Seminal vesicle – left side

■ Gleason 3 ■ Gleason 4 ■ Gleason 5

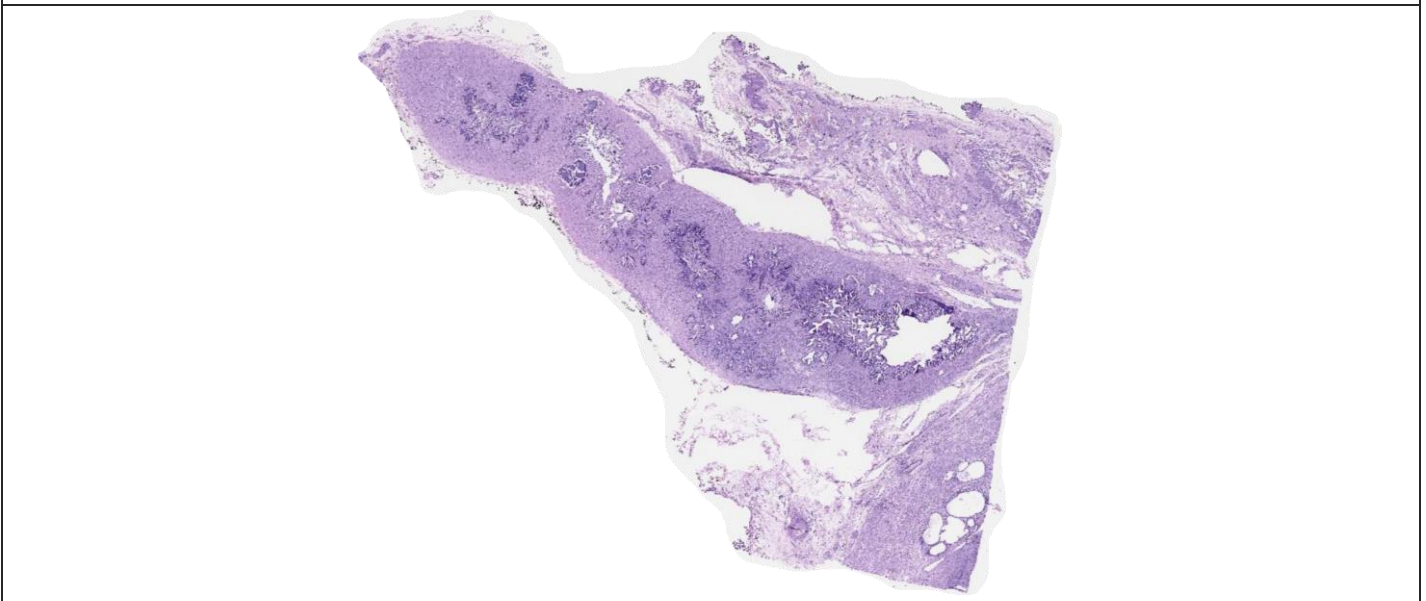
Slide 18 [REDACTED]



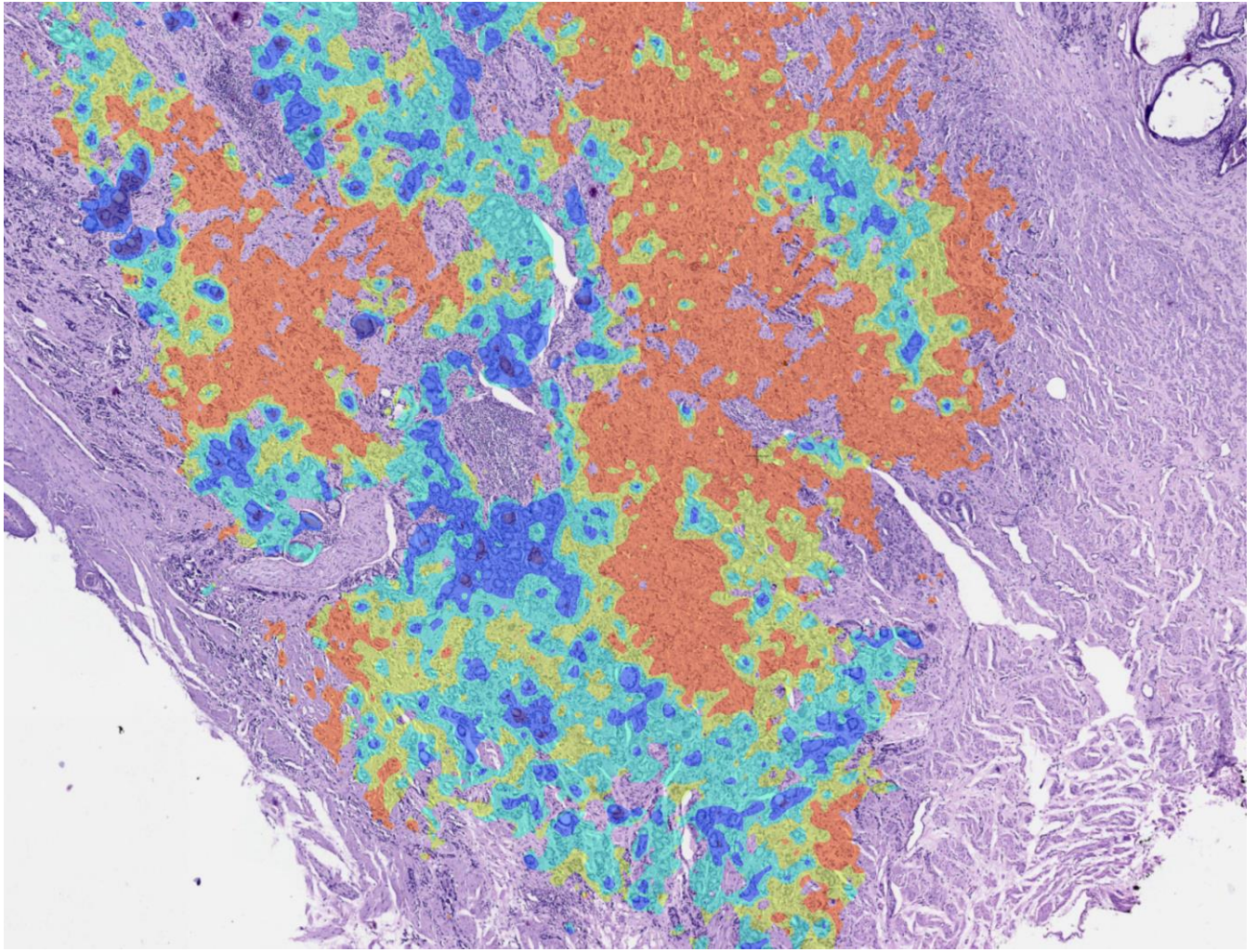
Slide 19 [REDACTED]



Slide 20 [REDACTED]



AI-supported Gleason score detection heatmap



Active Heatmap: **Gleason** Gleason 3  Gleason 5



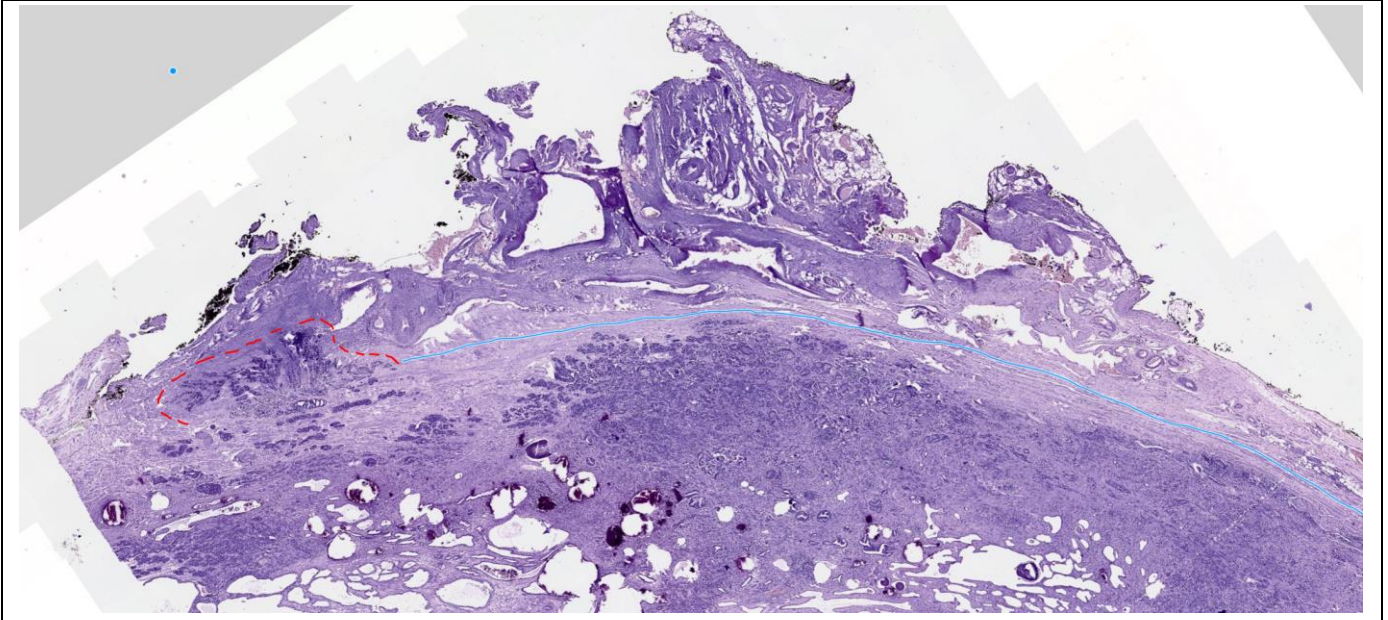
EXTRAPROSTATIC EXTENSION (EPE)

Present, extent **non-focal** (multifocal, bilateral).

Maximum distance of EPE from the established outer edge of the fibromuscular prostatic stroma – **2 mm**.

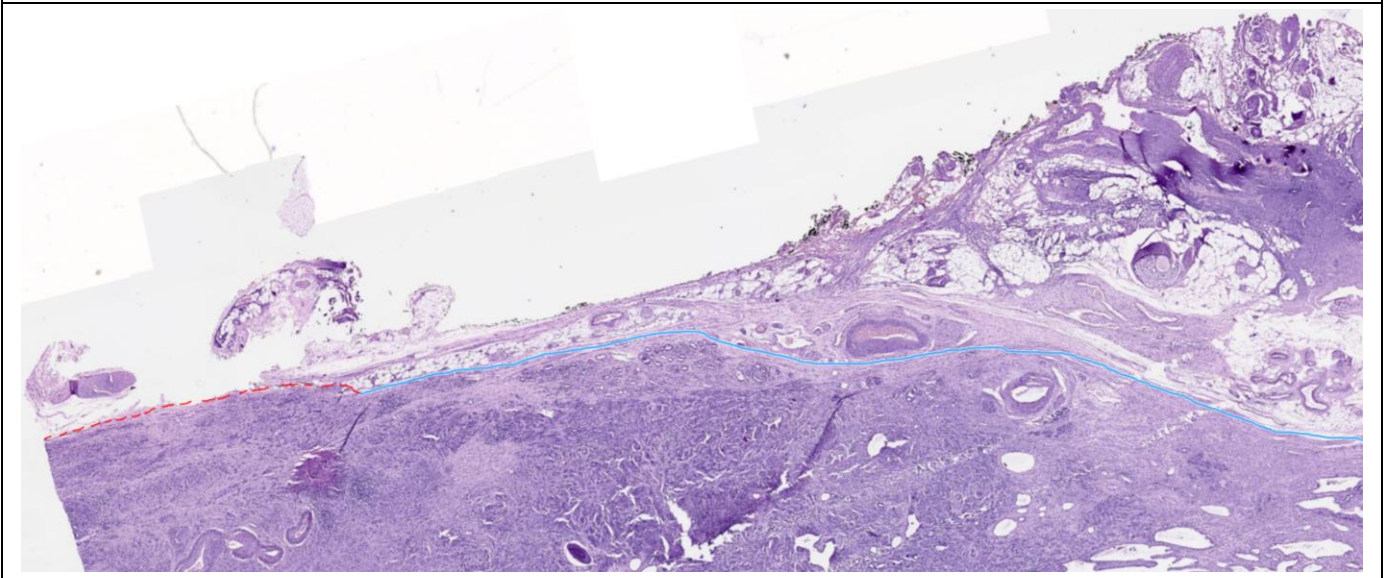
Areas with extraprostatic extension

Slide 02



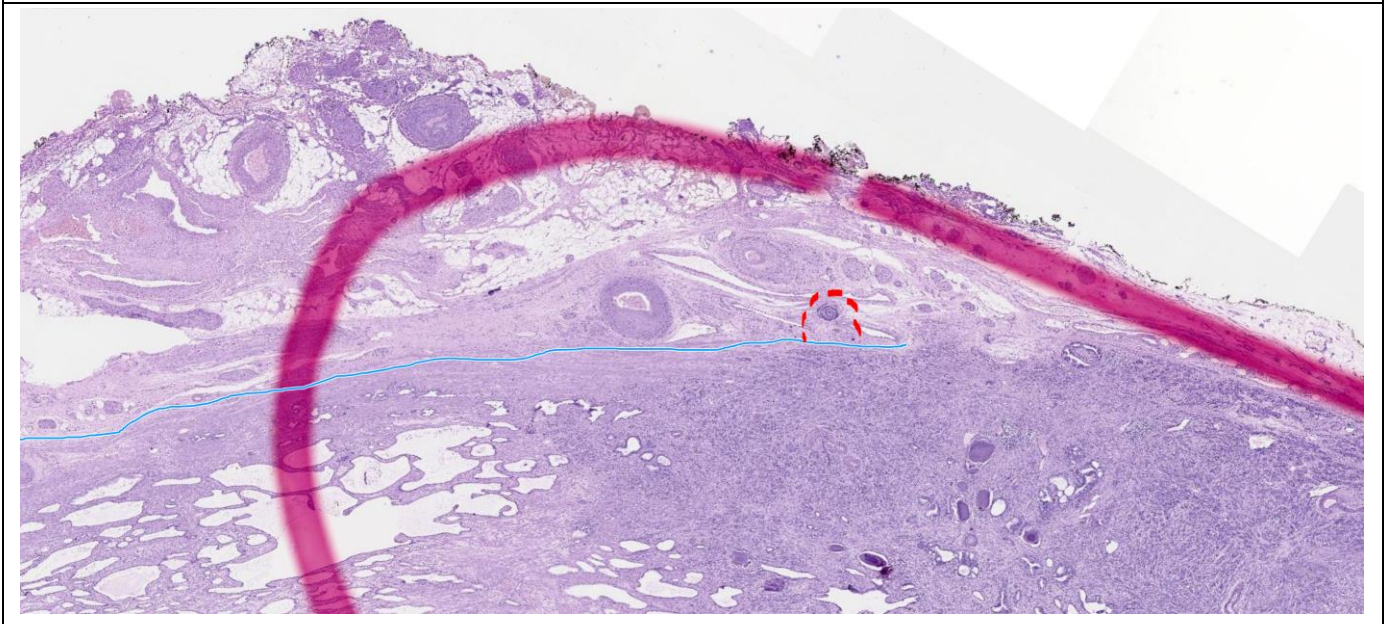
Areas with extraprostatic extension

Slide 07



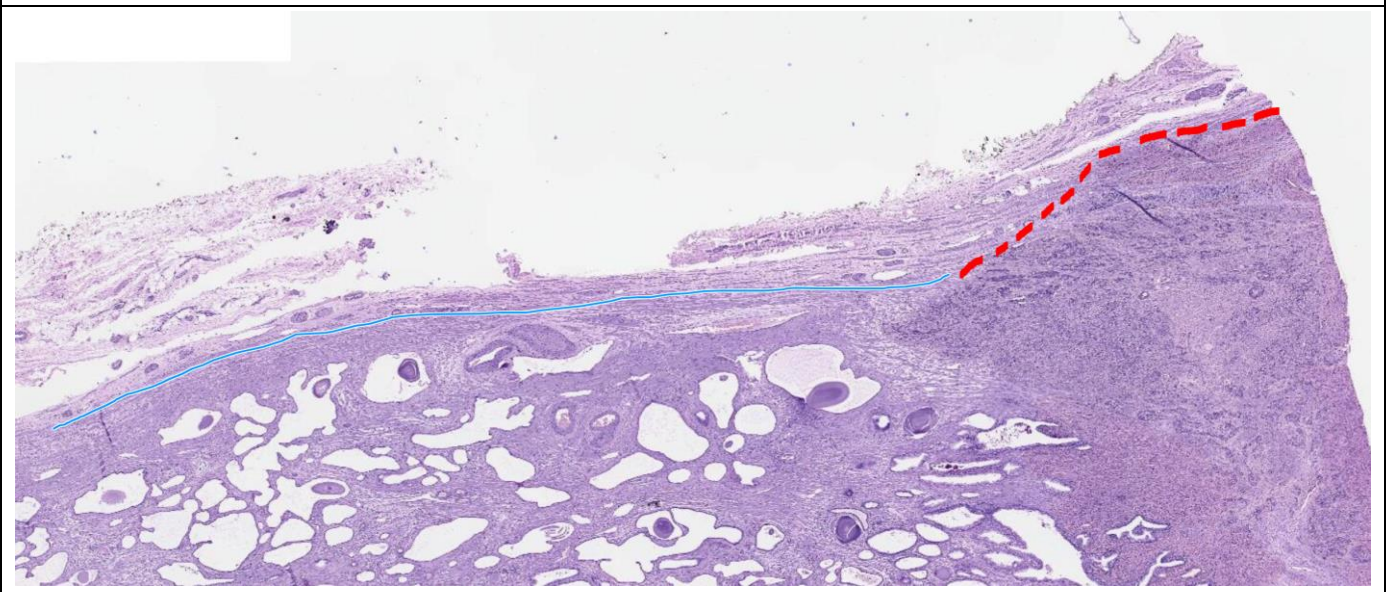
Areas with extraprostatic extension

Slide 09



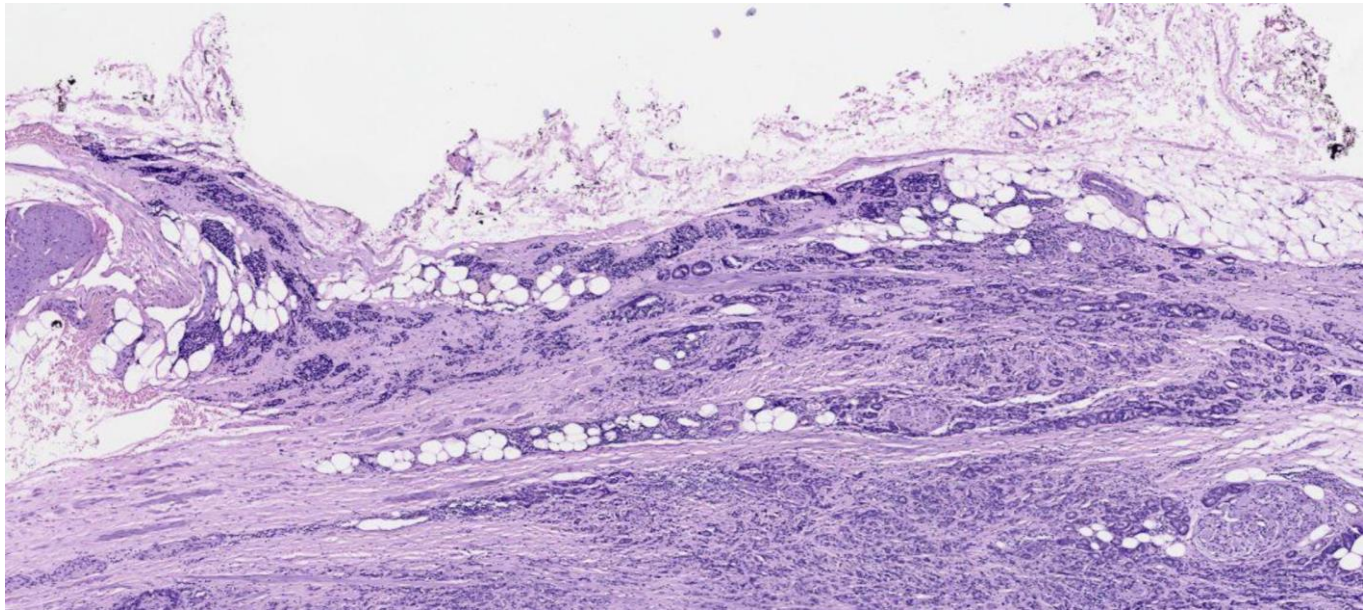
Areas with extraprostatic extension

Slide 26

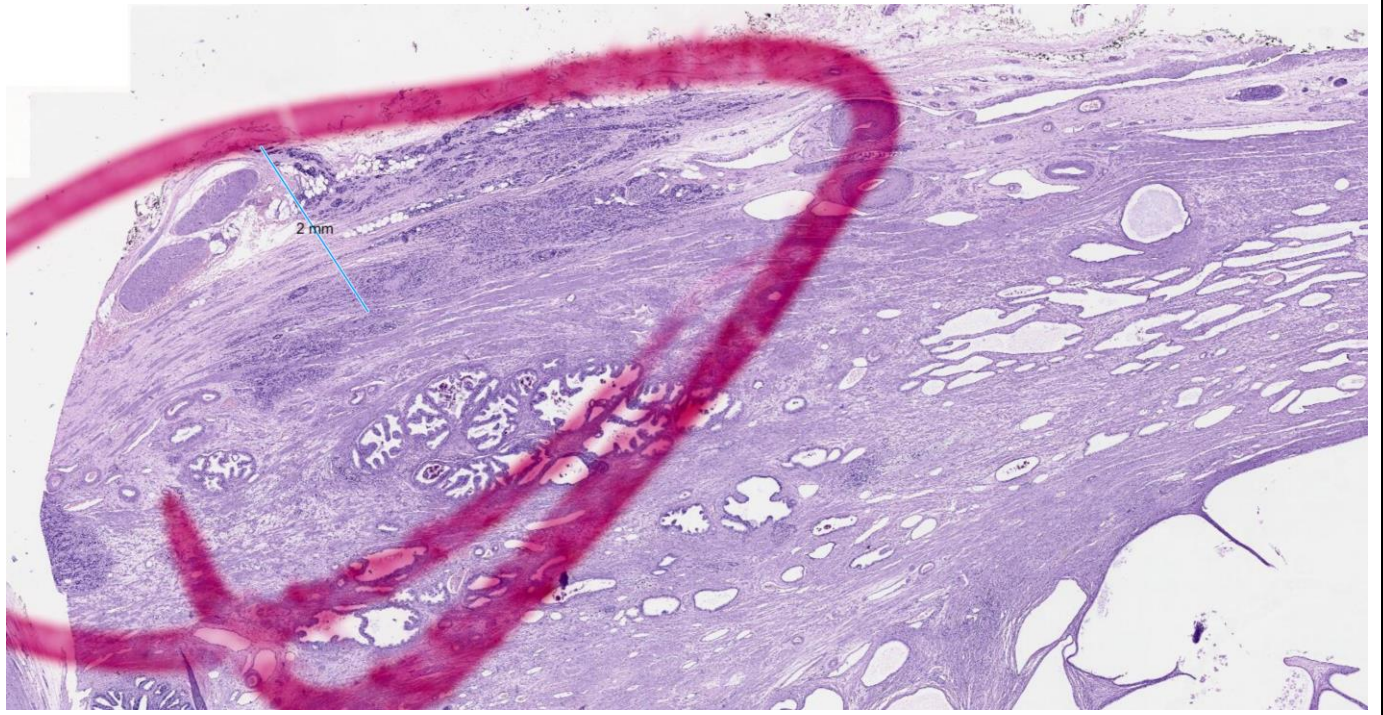


Areas with extraprostatic extension

Slide 26



Maximum distance of EPE from the established outer edge of the fibromuscular prostatic stroma – 2 mm.

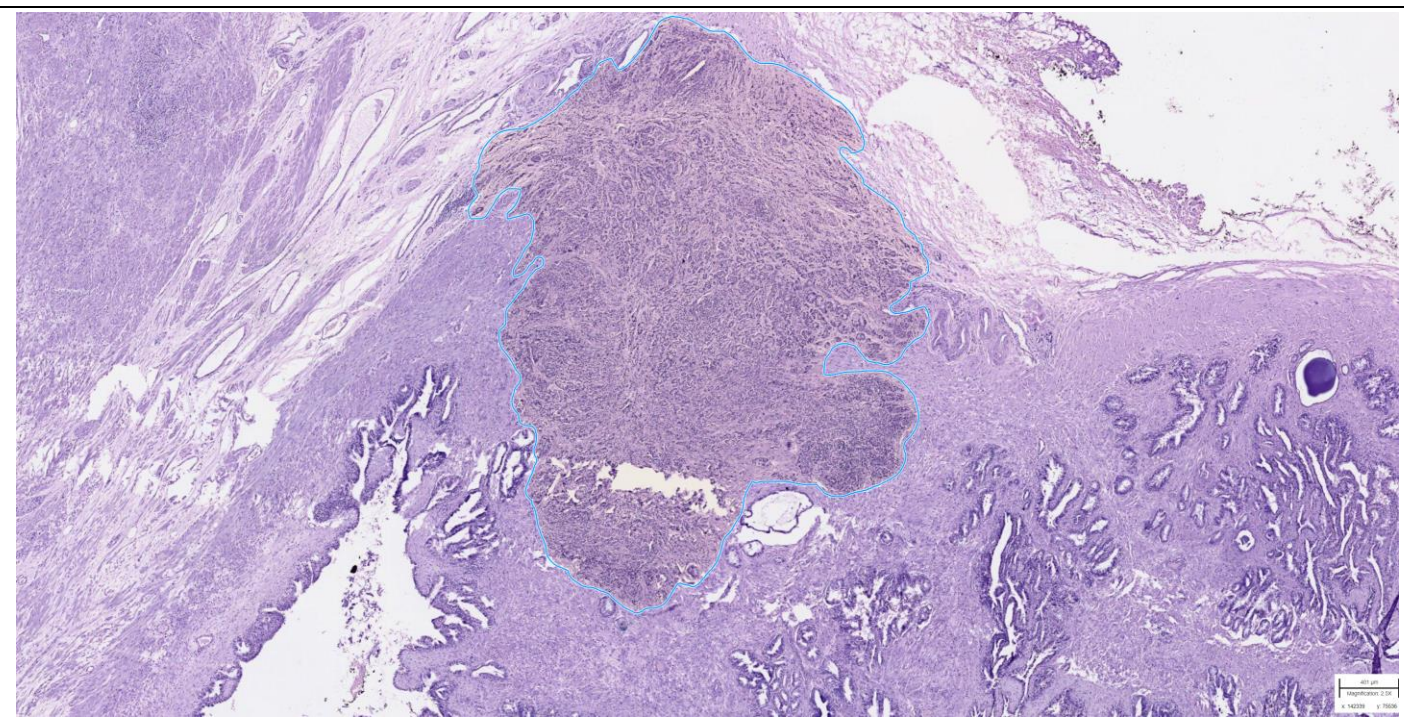


SEMINAL VESICLE INVASION

Present, right and left seminal vesicle

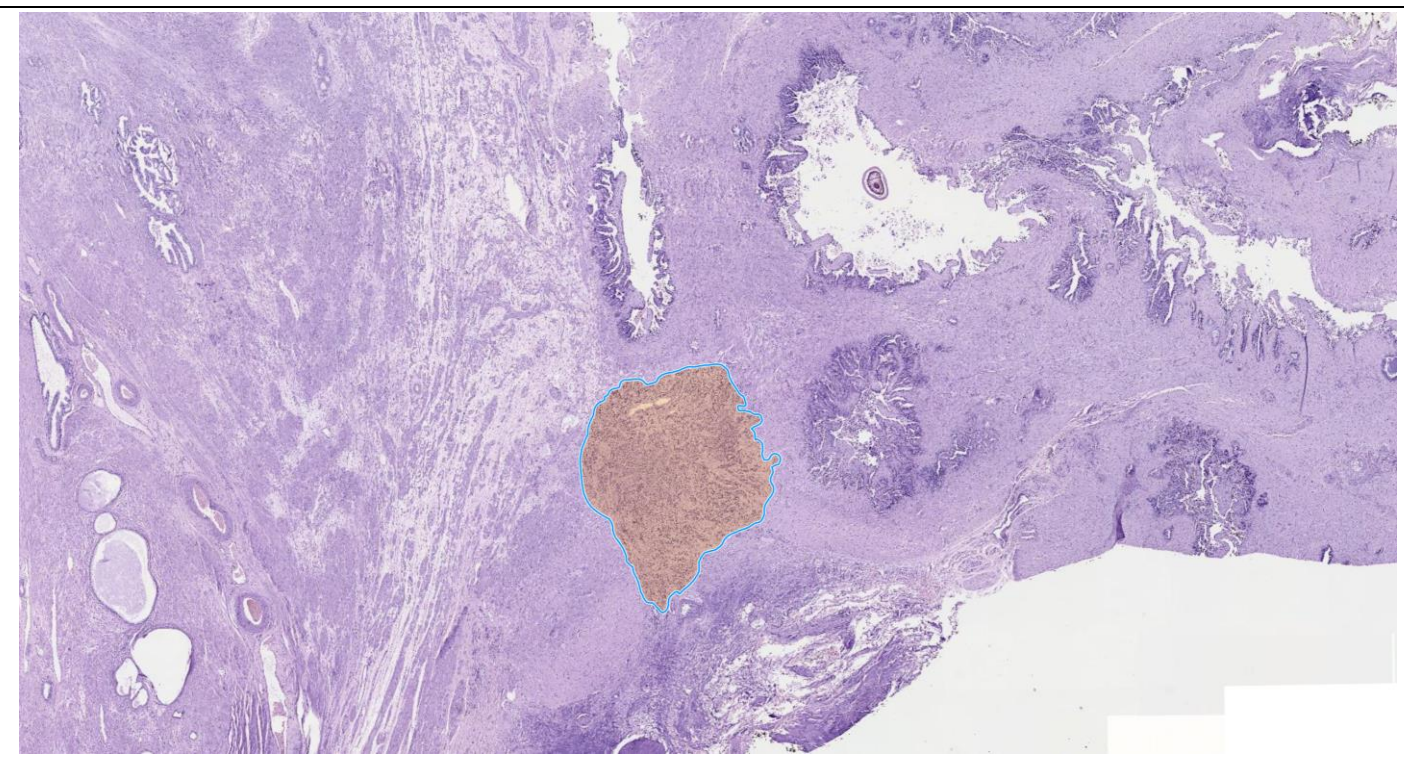
Areas with SEMINAL VESICLE INVASION

Slide 37 [REDACTED] Right side



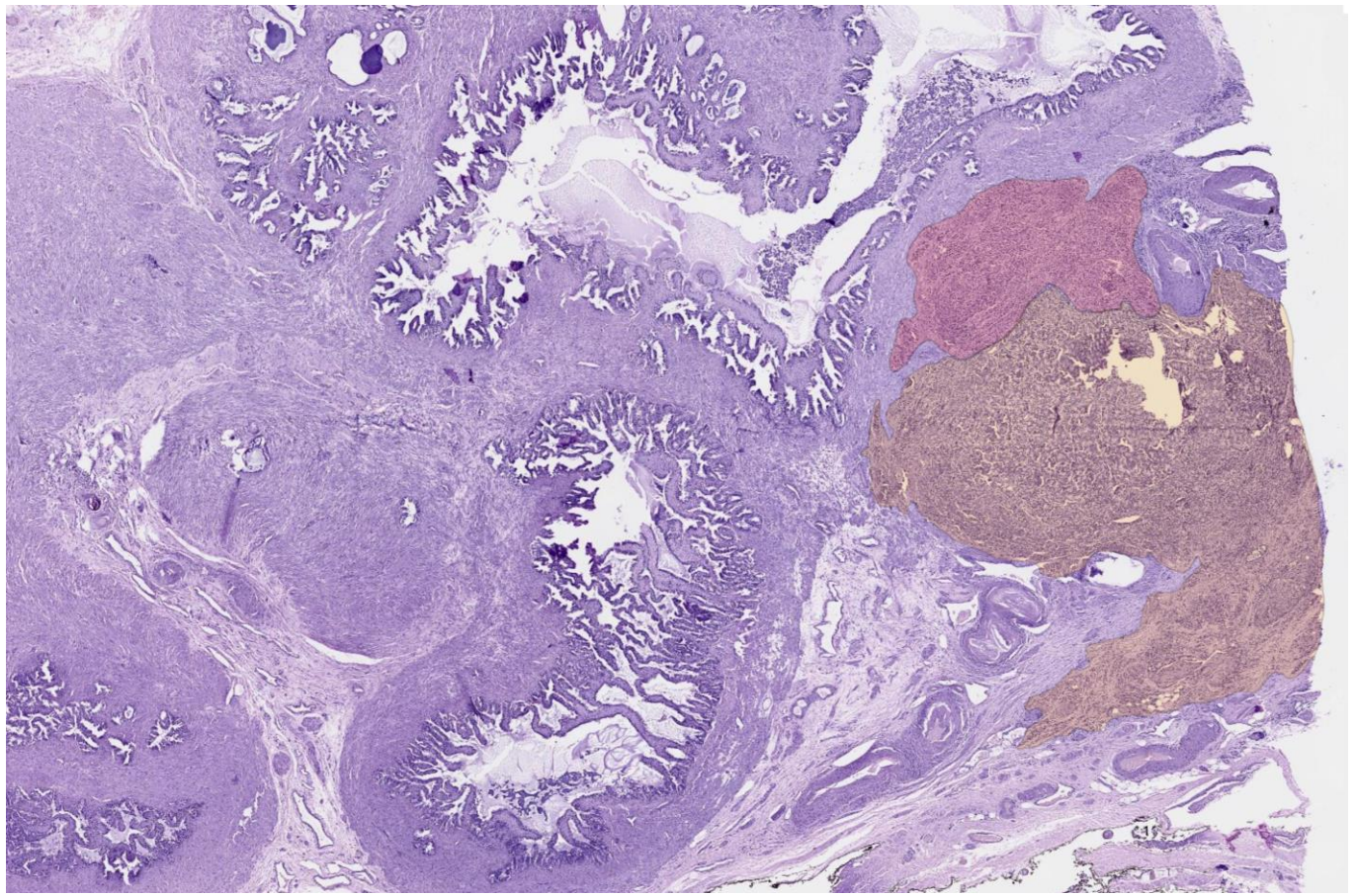
Areas with SEMINAL VESICLE INVASION

Slide 38 [REDACTED] Right side



Areas with SEMINAL VESICLE INVASION

Slide 19 [REDACTED] Left side



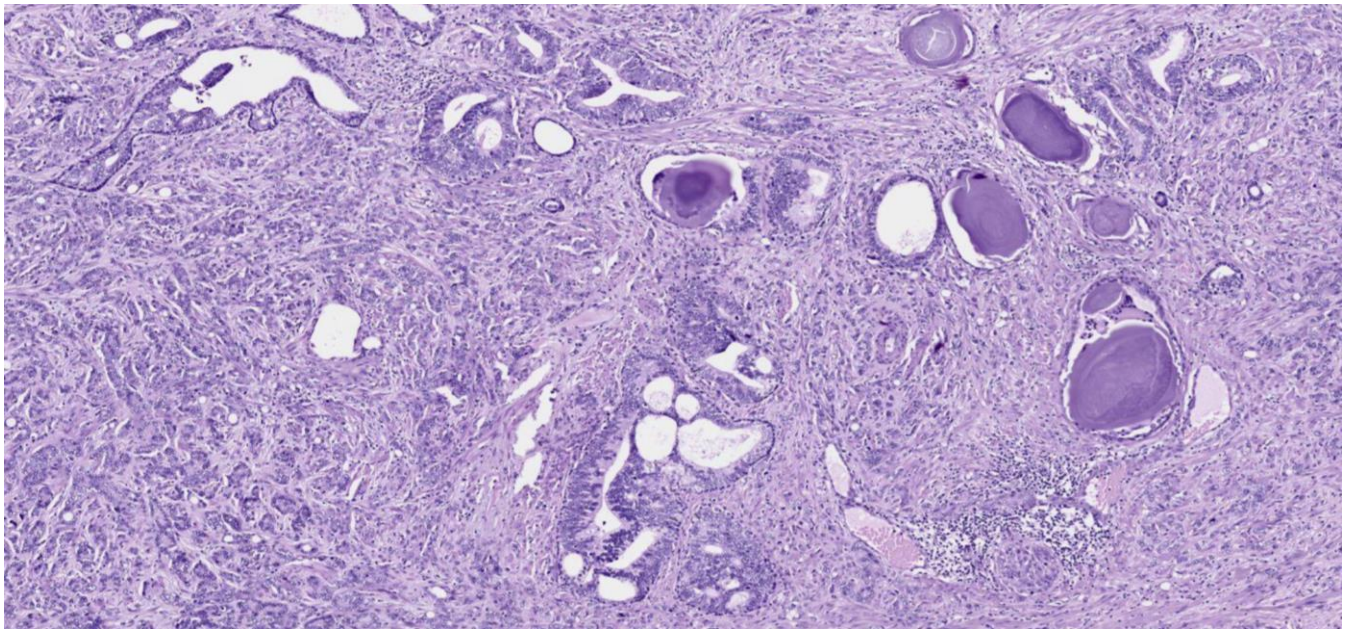
URINARY BLADDER NECK INVASION – Not identified

INTRADUCTAL CARCINOMA OF THE PROSTATE – Not identified

HIGH-GRADE PROSTATIC INTRAEPITHELIAL NEOPLASIA (HGPIN) - Present

HGPIN

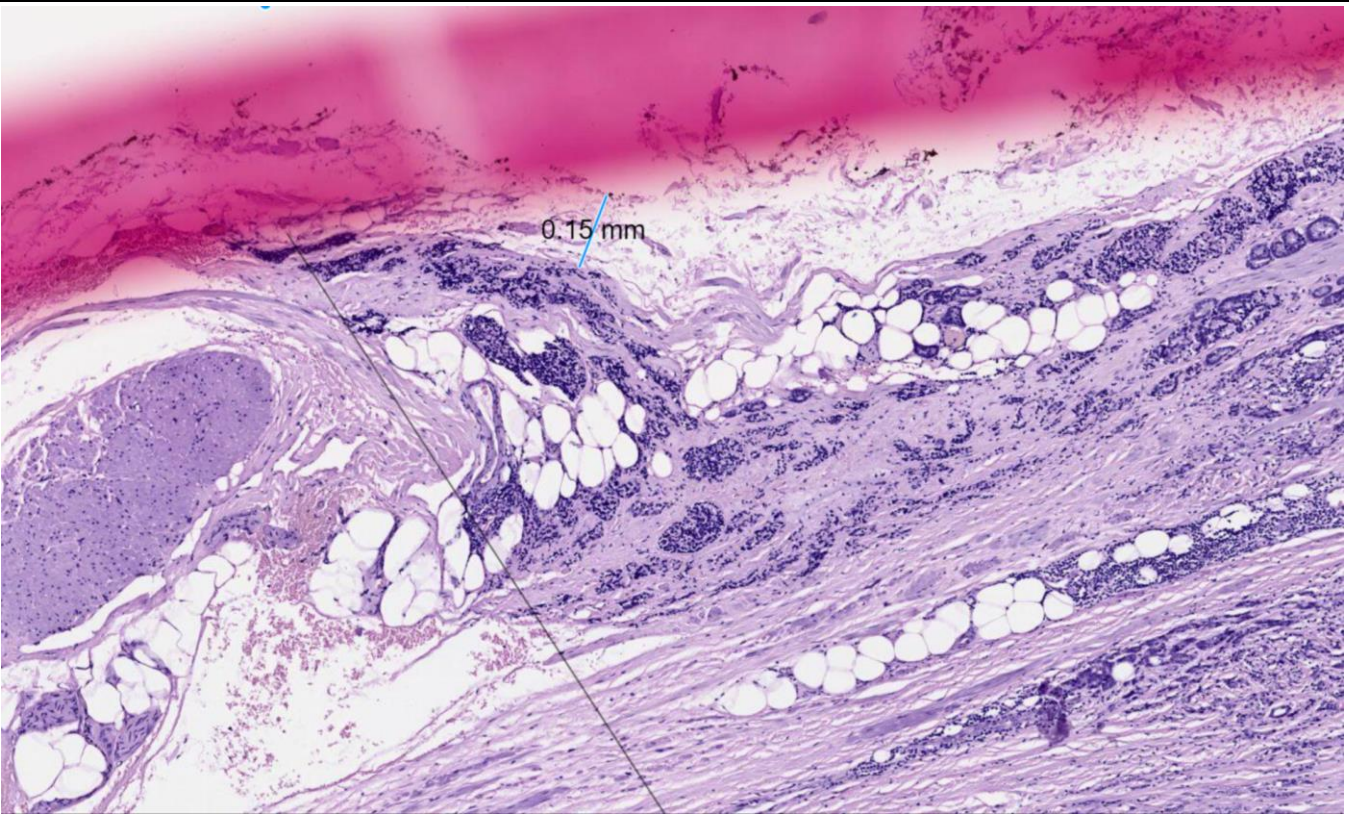
Slide 09



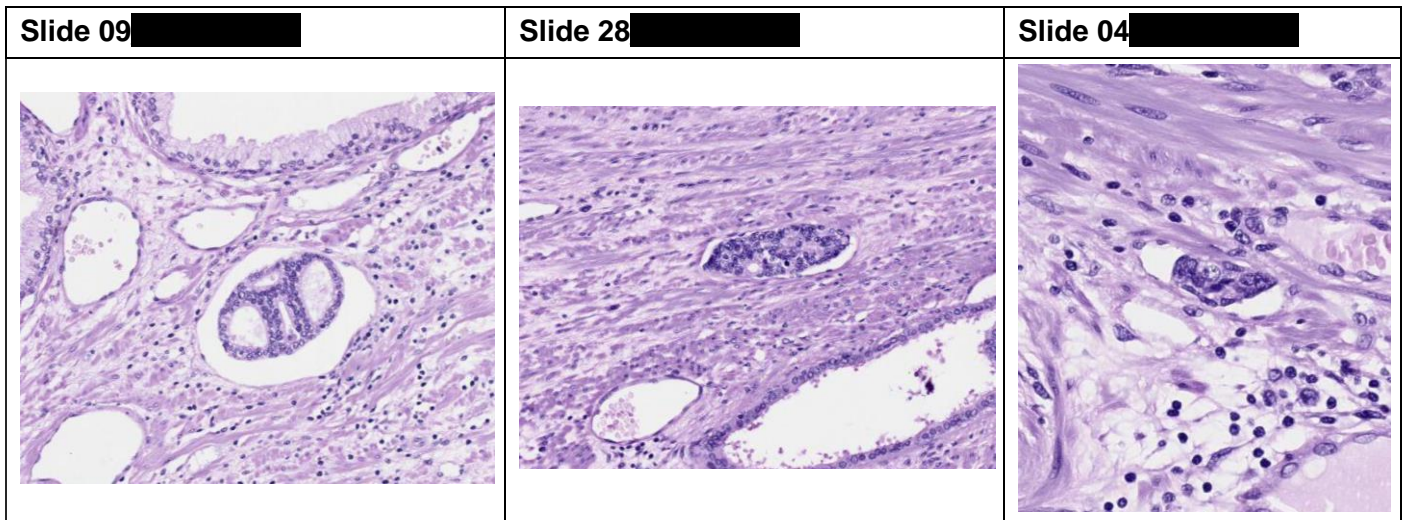
MARGIN STATUS – Not involved

Margin not involved, closest distance to inked margin – 0.15 mm

Slide 38 Right, posterior side of the prostate



LYMPHOVASCULAR INVASION – Present



LYMPH NODE STATUS

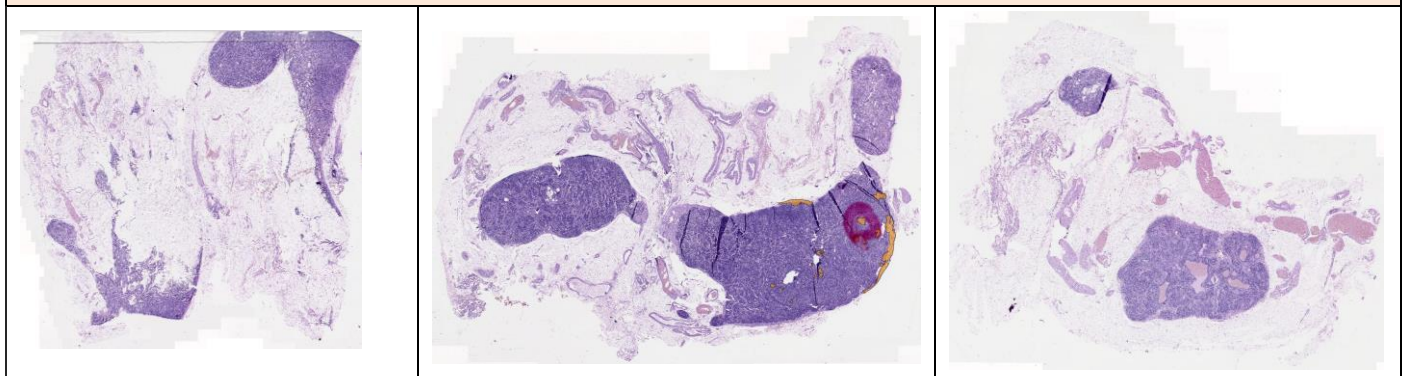
Number of lymph nodes examined: **10**

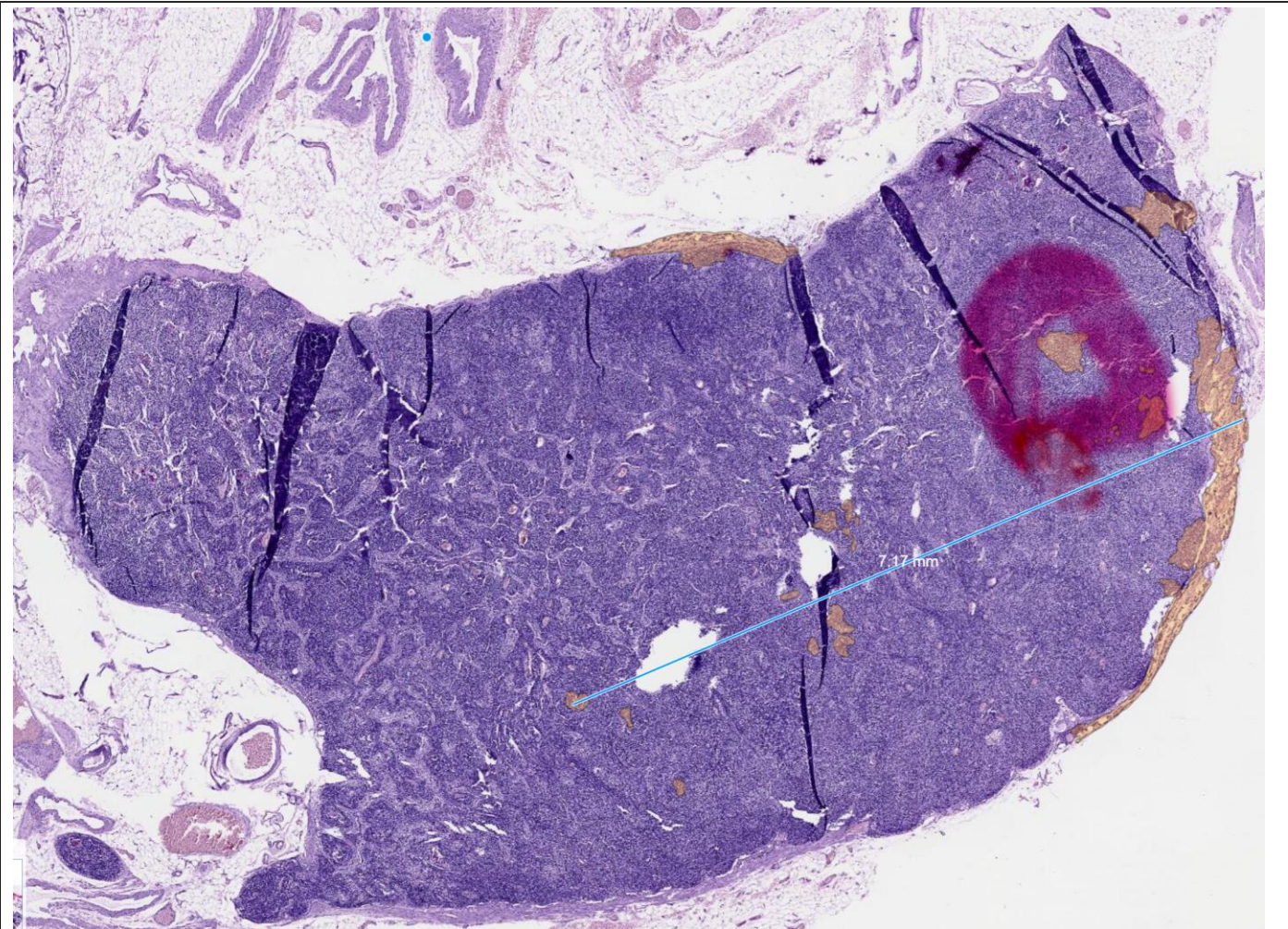
Number of lymph nodes involved: **2**

Laterality: **Bilateral**

Maximum dimension of largest deposit: **7.17 mm**

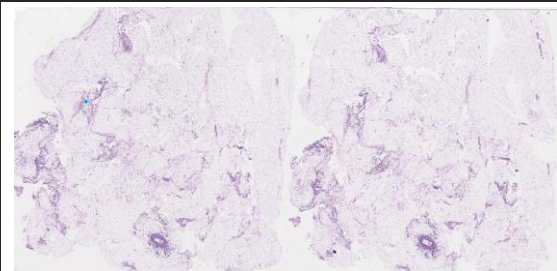
Left iliac lymph nodes – one of three nodes involved (1/3), max. dimension of metastasis 7.17 mm, extranodal extension present, metastasis Gleason pattern 4



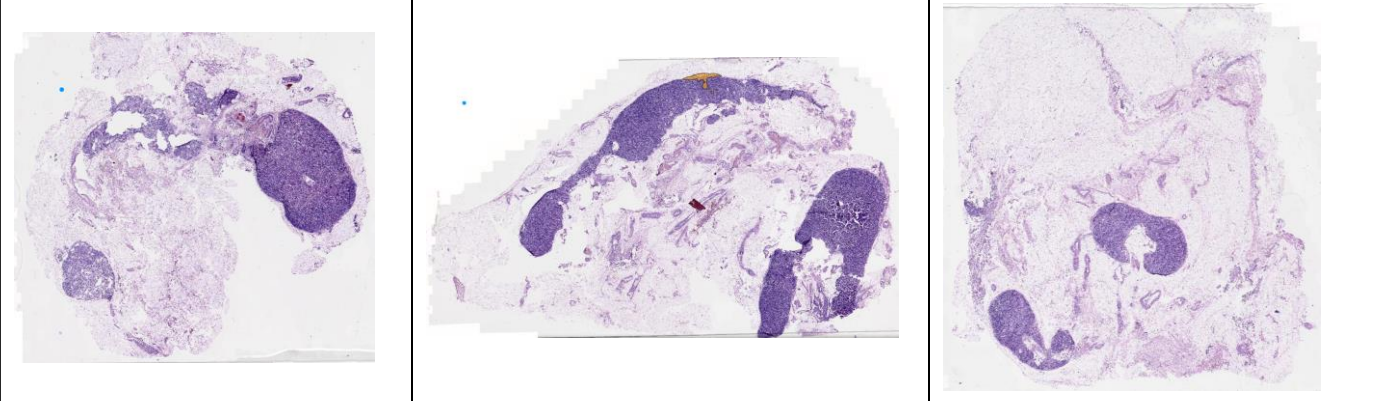

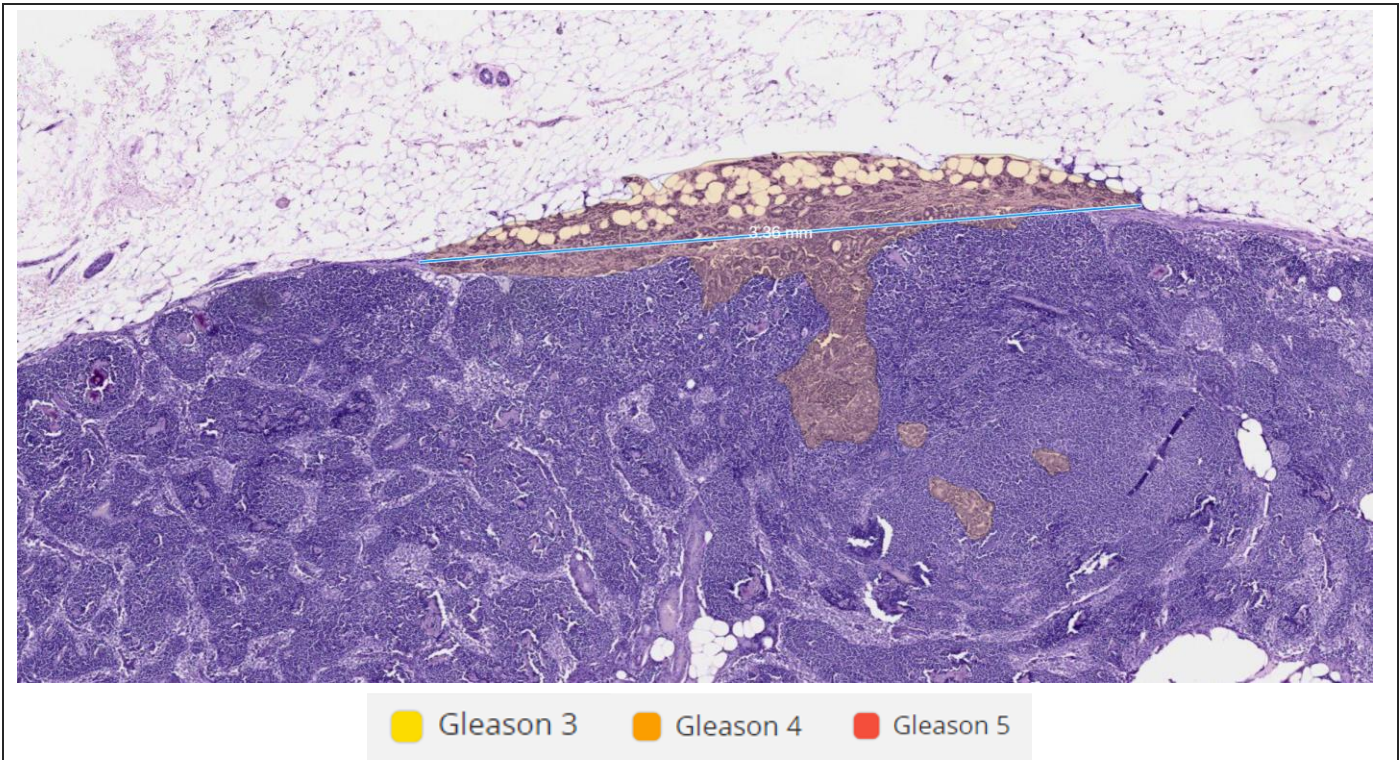
■ Gleason 3
 ■ Gleason 4
 ■ Gleason 5

Left obturator lymph nodes – no lymph node tissue identified



Right iliac lymph nodes – one of six nodes involved (1/6), max. dimension of metastasis 3.36 mm, extranodal extension present, metastasis Gleason pattern 4





Right obturator lymph nodes – one uninvolved lymph node (0/1)



Report details

Second opinion report issuing date: [REDACTED]

Report prepared and signed by:	Reviewed and signed by:

Contact

TwiceView second opinion service is provided by:

DIGITAL PATHOLOGY TEAM WITOLD REZNER sp. k.
Karczowkowska 45
25-713-Kielce
Poland
contact@twiceview.com

Electronic medical records

This document is an electronic medical record, signed and verified, in accordance with the rules set out in the Act of 28 April 2011 on the health care information system (Journal of Laws No. 113, item 657, as amended).